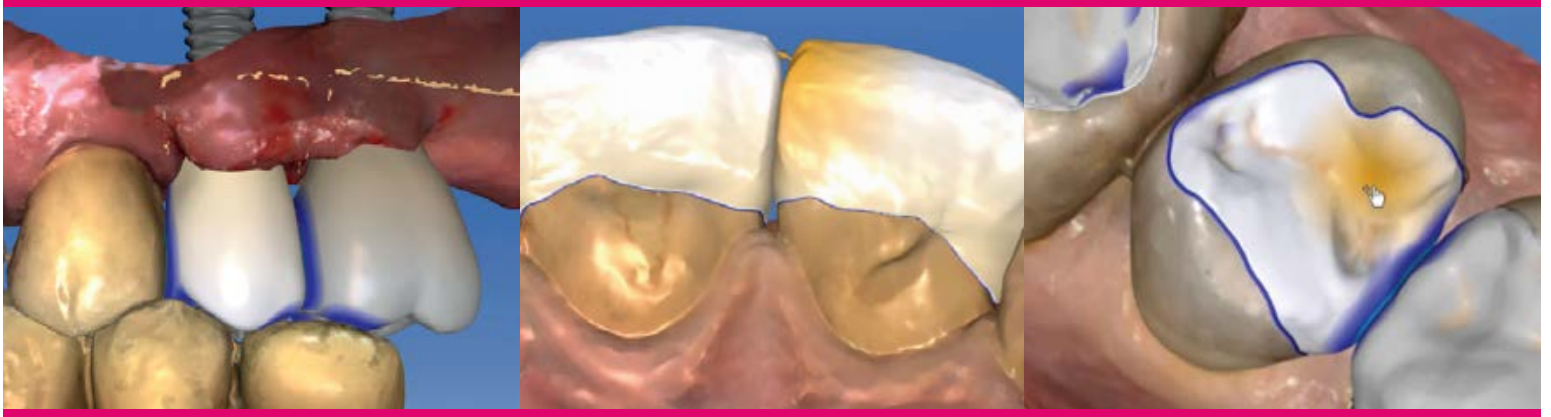
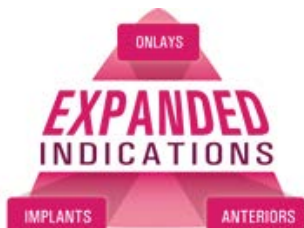

EXPANDED



INDICATIONS

CLINICAL WORKBOOK



VITA

Table of Contents

Section 1: Implant Restorations	1
Section 2: Anterior Restorations	23
Section 3: Onlays	35
Appendix	
1. Shade Measurement	48
2. VITABLOCS Preparation Design	50
3. VITA ENAMIC/VITA ENAMIC IS Preparation Design	51
4. VITA ENAMIC Bonding Protocol	52
A. Bonding to Tooth Structure	
B. Bonding to the Titanium Base	
5. VITA ENAMIC Polishing	56

Authors



Daniel Buttermann, DDS
Centennial, CO

Dr. Daniel Buttermann has been practicing general dentistry in Colorado since 1994. His technology-driven practice focuses on surgical implant placement and restoration. He is a Fellow of the International Congress of Oral Implantologists and a Master of the International Dental Implant Association. Dr. Buttermann utilizes Sirona 3D CBCT and CEREC technologies in his practice. He is a CEREC Doctors Mentor and an Advanced CEREC Trainer who has trained dentists throughout the United States.



Michael Skramstad, DDS
Orono, MN

Dr. Skramstad is a 2000 graduate of the University of Minnesota School of Dentistry. He is a certified advanced CEREC trainer and has lectured internationally on technology, implantology and digital dentistry. As a product consultant for multiple dental companies, he evaluates many products prior to launch and has published numerous articles on materials and CAD/CAM. He is a resident faculty member in the CAD/CAM Department of Spear Education and cerectoctors.com in Scottsdale, Arizona. He also maintains a successful restorative practice focusing on esthetic, implant and CAD/CAM dentistry.



Todd Ehrlich, DDS, FAGD
Austin, TX

Todd Ehrlich, DDS, FAGD, graduated magna cum laude from the University of Texas Health Science Center at San Antonio Dental School and served as president of its Alumni Association. He is a Master CEREC Trainer for Patterson Dental and Dentsply Sirona. Dr. Ehrlich is also a beta tester for Dentsply Sirona. He has lectured extensively on digital dentistry techniques and has published numerous articles. Dr. Ehrlich is the founder of DigitalEnamel.com and the Digital Enamel Education Center in Austin, Texas.

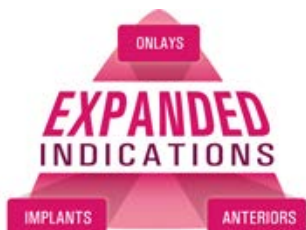EXPANDED



INDICATIONS

Section 1: Implant Restorations

Restorative Process for VITA IMPLANT SOLUTIONS



VITA

Clinical Considerations

Patient Consultation

Initial Consultation

The goals of the initial consultation are two-fold: First and foremost, the initial consultation should identify the patient's desired outcome. Second, the initial consultation should determine whether the implant restoration can be designed to accomplish the patient's goal, and at the same time to provide a long-lasting, functional and esthetic result.

Understanding Patient Needs and Setting Expectations

When a patient presents with a missing tooth, the goal is to create a prosthetic that can replace the original body part in form and function with no perceptible difference between the natural tooth and the implant restoration. Patients want their implants to look and feel as good, if not better, as their natural teeth looked and felt. And they want their tooth as quickly as possible, not in multiple appointments spanning several weeks.

The primary reason dentists use chairside CAD/CAM systems is to deliver a high quality restoration in a single visit. Before VITA ENAMIC IS (Implant Solutions), it was not feasible to do an implant restoration in a single visit. The typical workflow was to image the patient in one appointment, and schedule the patient for a second visit to deliver the restoration – exactly how it was done in the analog days before chairside CAD/CAM.

VITA ENAMIC IS and VITABLOCS TriLux forte enable us to deliver implant restorations in a single visit. With VITA ENAMIC IS, the dentist also has the option of highly polishing the restoration, or staining and glazing the restoration with light-curing stains to mimic the look and feel of a natural tooth. A successful implant is not just a screw integrated into bone, but a fully functional tooth that looks and feels natural. VITA ENAMIC IS makes this possible.

Questions to consider during the diagnostic process:

- Evaluate bone volume and density. Is the bone condition suitable for an implant?
- Is the soft tissue/mucosa thick enough and healthy? Adequate keratinized tissue should be present to maintain implant health. Additionally, if the tissue is too thin, the implant or abutment collar has the potential to show through.
- Is the right angulation possible for a screw-retained restoration (abutment crown) or should it be cement-retained (mesostructure)?

Treatment Planning

Imaging

Using VITA ENAMIC IS, cone beam technology, implant planning software, milled or printed surgical guides, and a fully digital workflow with chairside CAD/CAM, teeth can be replaced in as little as two visits from implant placement to final restoration. It is beyond the scope of this workbook to teach proper implant planning and surgical techniques. For purposes of this workbook, it will be assumed that the implant has been placed properly and is fully integrated with adequate attached gingiva. The clinician should evaluate the implant angulation and the surrounding teeth to ensure adequate restorative room to place a properly functioning abutment and crown. A minimum of 5 mm inter-occlusal space from the implant platform is necessary to produce a screw-retained crown and 7 mm for a separate abutment and crown.

Questions to consider during the treatment planning process:

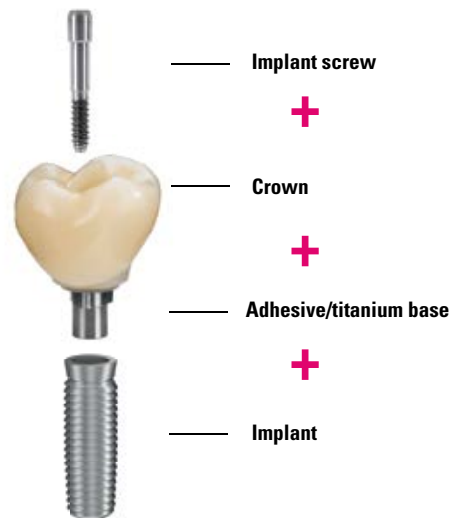
- Is there adequate occlusal clearance?
- What are the patient's cosmetic requirements?
- Is there adequate keratinized gingiva and proper gingival contours?
- Where will the screw access hole emerge from the restoration?
 - **For anterior implant:** Will the screw access hole emerge out of the lingual side of the incisal edge (through the cingulum?)
 - **For posterior implant:** Will the screw access hole emerge through the occlusal table?
- Is the implant path of insertion parallel with the contacts of the adjacent teeth to allow for seating of a screw-retained crown?

Types of Implant Restorations

Abutment crown

A screw-retained restoration is a milled crown with screw access channel through the crown. The crown is adhesively cemented to a TiBase. This assembly is “bolted” down to the dental implant.


For a screw-retained crown, you will need a size 16 L or S block, depending on the implant type. The screw access hole must be positioned through the central fossa, or the cingulum in the case of anteriors. For this type of restoration, you need only 1 mm of occlusal thickness over the TiBase. The implant must be placed relatively parallel to the contacts of the adjacent teeth for a path of insertion that will allow the TiBase to seat into the implant without interference from the contacts. It is more difficult to adjust contacts on a screw-retained abutment crown. However, if you over-adjust, VITA ENAMIC IS allows you to add contacts back on quickly and easily with composite. This restoration can be polished only, or stained and glazed with light-curing stains and glaze. As with all screw-retained restorations, there is no chance of cement sepsis. Because VITA ENAMIC IS mills quickly and needs no furnace time, the screw-retained abutment crown can be fabricated easily in a single visit.



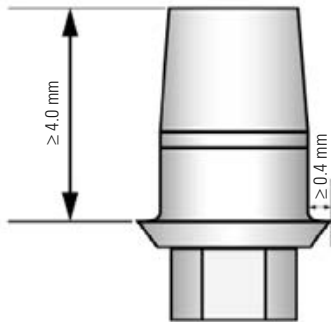
Mesostructure with cement-retained crown

A cement-retained restoration is a combination of two pieces: (1) a milled crown, which has been cemented to (2) an underlying abutment post (the abutment post can be described as a substructure or mesostructure).

For a multi-layer custom abutment and crown, the abutment must be milled out of a size 14 block. It is easier to seat this restoration because it allows for a correction of the implant angle up to 20 degrees with no path of insertion issues. The milled custom abutment can be placed at time of implant surgery or implant uncover to sculpt the tissue and function as a custom healing abutment. The abutment margin should be placed in a manner to allow for easy cement cleanup. The abutment color can be matched to the crown color, and the margin left supra gingival if needed. Should minor gingival recession occur over time, it is less noticeable. The warm color simulates dentin under the crown and produces the ultimate cosmetic result. Because it is necessary to mill two blocks for this restoration, it requires a longer processing time.

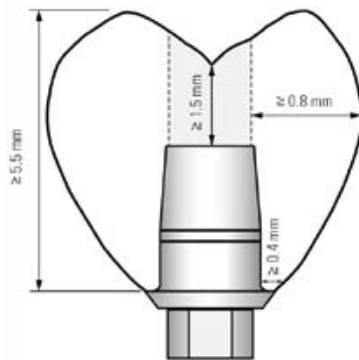


Restoration Design



Dimensions of the titanium base

Height of adhesive surface: min. 4.0 mm
Marginal shoulder width: min. 0.4 mm



Dimensions of the restoration

— 1 mm is needed for VITA ENAMIC IS

— 4.5 mm total TiBase height:
Approx. 0.5 mm collar and 4 mm post

For the most up-to-date list of available TiBases, visit
www.vita-zahnfabrik.com/VITA_ENAMIC_IS#titan_compatibility

Material Selection

Function and Esthetics

VITA ENAMIC IS can be highly polished or stained and glazed with light-curing stains. When bonded to a VITABLOCS TriLuxe forte crown, VITA ENAMIC IS has a warm, dentin-like color. In the event a patient has some recession over time, an VITA ENAMIC abutment will mimic root surface color. This will look far more natural than recession on an opaque zirconia abutment or a gray titanium one. Contacts or occlusion can be added to VITA ENAMIC with composite even after it is bonded to the TiBase. No alteration is possible to IPS e.max CAD Abutment Solutions, or any other material that needs to be fired in a furnace. Due to the resiliency of the material, it may help distribute occlusal forces away from the screw and crestal bone.

Processing Time

VITA ENAMIC IS processes quickly because no furnace is needed, making it an ideal chairside restoration material with excellent results. It can be used to restore an implant in a single visit, in approximately the same amount of time as it takes to fabricate a crown for a natural tooth.

Marginal Integrity

VITA ENAMIC IS provides an accurate fit and precise margins. It is less likely to chip at the abutment/titanium base juncture, which is prone to thinning margins. As such, VITA ENAMIC IS offers an excellent transition for biocompatibility and reduces the likelihood of tissue irritation.

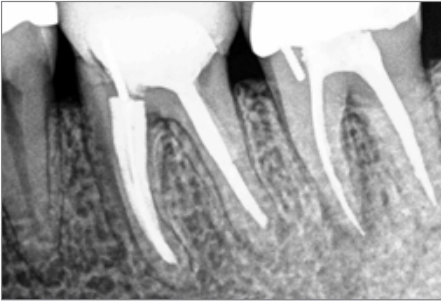Bite Force and Load Management

Since there is no periodontal ligament or Sharpey's fibers, the implant is static and does not move like other teeth. Bite force with an implant increases up to five times, and overload of the implant can lead to marginal bone loss if left unchecked. VITA ENAMIC IS offers the benefit of being rigid enough to stay in place and flexible enough to act like a shock absorber, diffusing and depleting forces away from the implant and biomechanical interface.

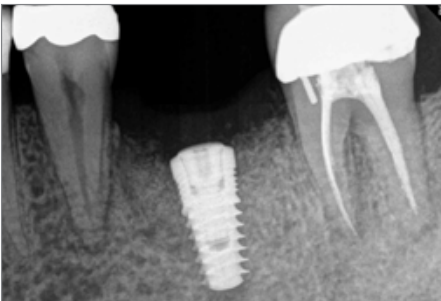Implant Restoration on Tooth #19 with Screw-Retained VITA ENAMIC® IS

Daniel Buttermann, DDS – Centennial, CO

Patient Presentation



The patient, a 38-year old healthy male with an unremarkable medical history, presented with a non-restorable tooth #19. The tooth had a vertical root fracture and recurrent decay. The patient was given an option for an implant at site #19 or a fixed bridge from teeth # 18-20. The patient elected to have the tooth extracted and an implant placed immediately at the time of extraction. The implant placement was planned using a CBCT scan and Galaxis software.



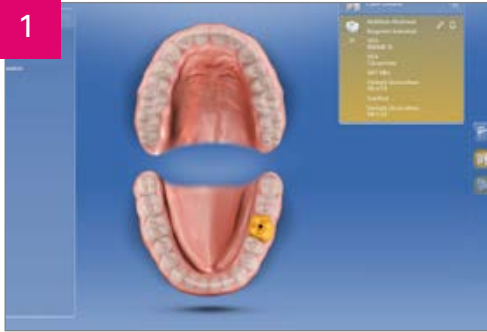The clinical crown was sectioned off and the initial osteotomy was performed through the furcation of the tooth to keep the implant centered. The roots of #19 were then removed atraumatically, and the osteotomy was completed. A 5x10 mm Implant Direct Interactive implant was placed and torqued to 40 Ncm. The site was grafted with a cortico-cancellous mix of DFDBA bone and sutures were placed. The site was allowed to heal for three months, at which time the patient returned for his final restoration.

Armamentarium

- Chairside CAD/CAM system
- Scan post and scan body to image the implant platform, angulation and timing into the CAD/CAM system.
- TiBase specific to the implant connection and platform diameter.
- VITA ENAMIC IS size 16 or 14 L or S, depending on the type of restoration and implant type.
- Multilink hybrid abutment cement to join the abutment to the TiBase.
- Hydrofluoric acid for etching
- Silane for intaglio surface of restoration
- VITA Easyshade V
- VITA ENAMIC Stains Kit
- Curing light

Administration

1

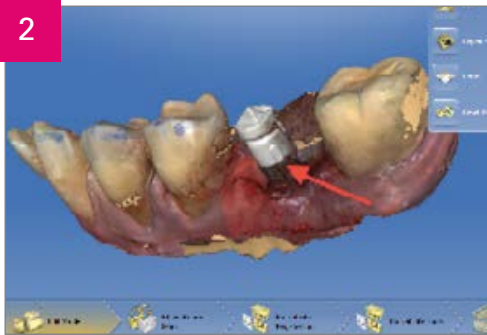


Always set up as multilayer restoration, even if you plan on a screw-retained restoration.

- Select VITA ENAMIC IS as the abutment material.
- Select VITA ENAMIC as the veneering material.
- Select the appropriate TiBase for implant brand and platform size.
- Always use a scan post to image the implant platform and timing.

Imaging

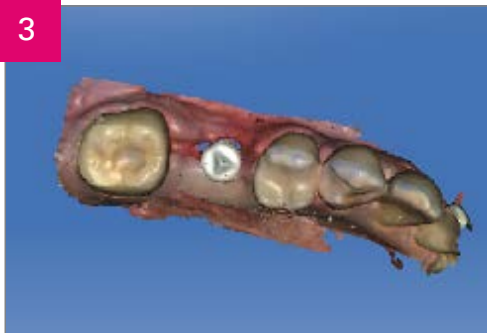2



Tips:

- Make sure the scan post is fully seated on the implant and verify with an X-ray.
- For a screw-retained crown (= abutment crown), it is best to place the scan post notch interproximally because the sprue will mill 90 degrees from the notch. For an abutment, notch position is not an issue because the software will position it using different criteria.
- Make sure scan body is correctly seated over notch of scan post.
- The shiny scan post may be difficult to scan. Focus on scanning the area where the scan post meets the gingiva. If you do not have enough scanned data, the software may assume the scan post is an artifact and remove it from the image.
- Before dismissing the patient, always move forward to making the models step to confirm that all imaging is accurate.

3

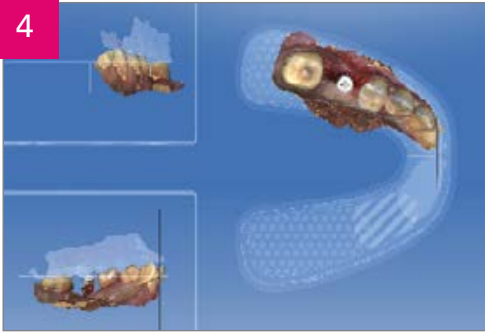


Steps:

- Add gingival mask catalog.
- Remove healing abutment and scan gingiva. Be sure to catch the contacts of the adjacent teeth as this will be more difficult to accomplish once the scan post is placed.
- Scan opposing arch and buccal bite.
- Copy gingival mask scan to the restoration catalog (upper or lower arch).
- Use the Cut Tool to remove a small area around the implant.
- Place scan post and image just enough to fully fill in the scan post data.
- Verify stitch of gingival mask, move forward to models and dismiss patient, or continue with restoration if doing in a single visit.


Design

4



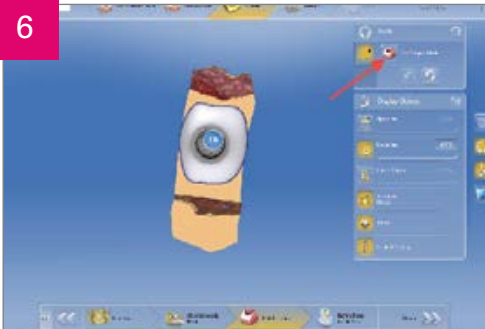Set the model axis.

5



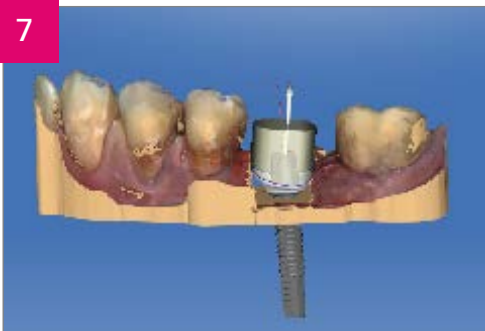
Trim model and click on scan body head.

6



Uncheck "use gingiva mask" unless the tissue has been well sculpted for the restoration.

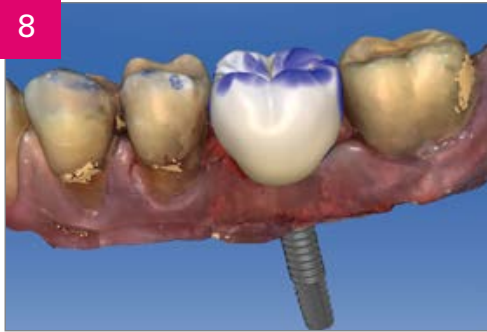7



Verify path of insertion and abutment angle.

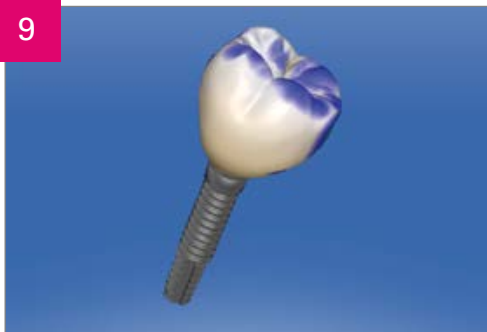Implant Restoration on Tooth #19 with Screw-Retained VITA ENAMIC® IS

8



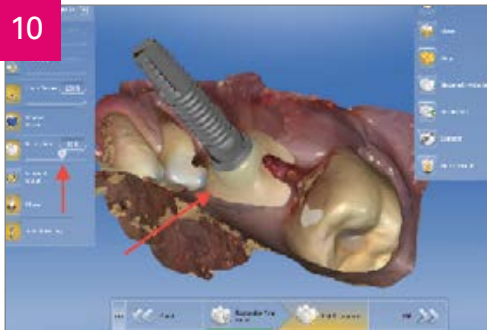Design full contour restoration as usual, for the moment ignoring the sub-gingival areas (restoration thickness, contour, occlusion, contacts).

9



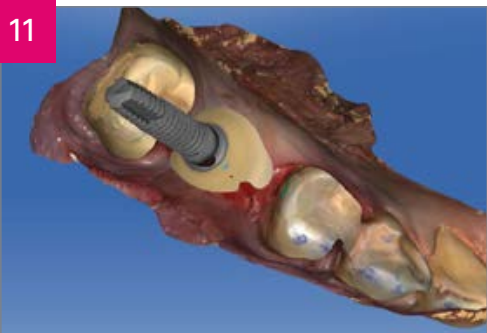
Under display, remove the model arch that you are working on, and adjust the emergence and contours of the sub-gingival areas so that they are smooth and flowing.

10



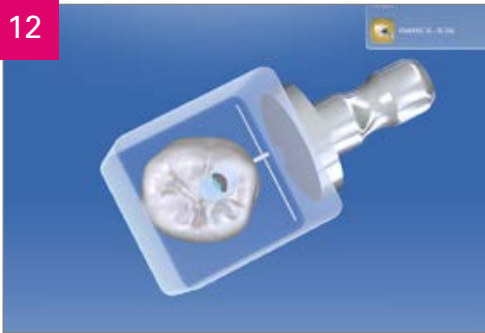Turn on the gingiva mask folder and make the restoration slightly translucent to evaluate the amount of pressure that will be placed on the tissue. Any white restoration show-through will be pressure on the tissue. Any tissue show-through will be a void.

11



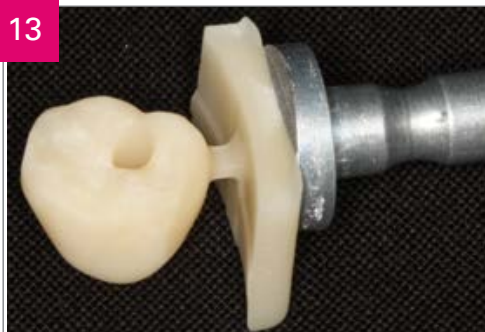If there is too much tissue pressure, it may be necessary to do a mid-crestal incision at delivery. When placing, my rule of thumb is that any blanching should subside within approximately 5 minutes.

12



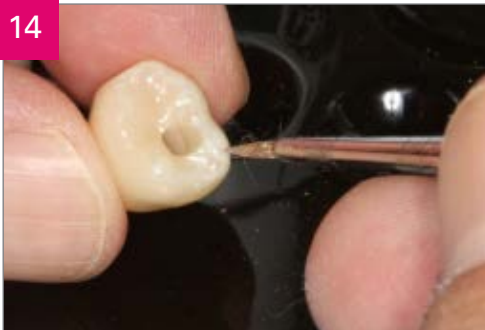After the full contour restoration is designed, proceed to mill. An VITA ENAMIC IS 16 L block in shade 2M2 was selected. Milling time was about 20 minutes.

13



Remove the sprue and characterize as desired. Refer to the Appendix section titled **VITA ENAMIC Polishing** for the polishing protocol.

14



Blue and white VITA ENAMIC STAINS were added around the cusps for a translucent effect and brown in the grooves to provide depth. The restoration was then light cured. VITA ENAMIC GLAZE was added on top and light cured. Recommended: Etching of crown surface (5 % HF, 60 sec) for optimal retention of the light curing stains.

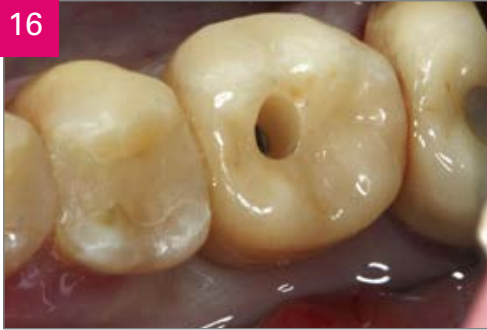15



Bond the finished VITA ENAMIC IS crown to the TiBase. Refer to the Appendix section titled **Bonding to TiBase** for the proper protocol. Note the excellent marginal fit to the TiBase collar.

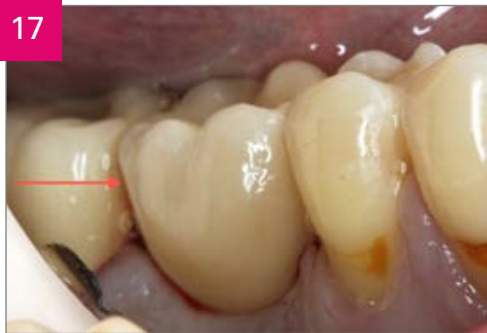Implant Restoration on Tooth #19 with Screw-Retained VITA ENAMIC® IS

16



The crown was torqued into the implant, contacts and occlusion were checked and Teflon placed into the screw access hole. Composite was placed to close the access hole and the patient was dismissed.

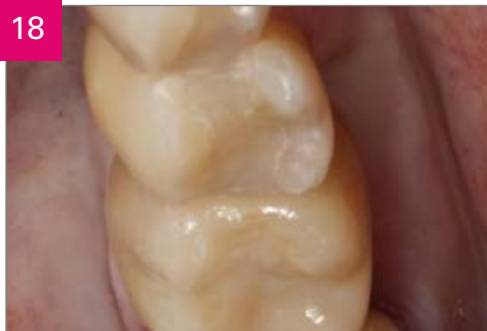17



Total time from patient being seated to dismissal was an hour and twenty-five minutes.

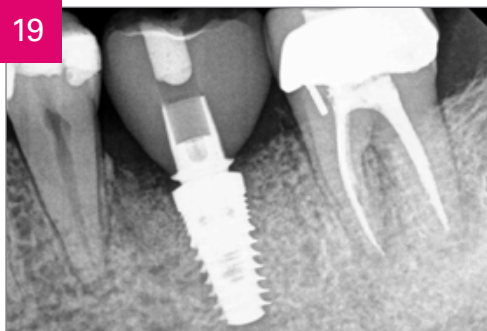Result

18



The finished result shows excellent fit and shade match.

19



The use of a resilient material on a rigid implant may help distribute forces away from the screw and crestal bone, possibly improving the longevity of the implant and restoration.

U. S. Insurance

Always consult with the insurance provider for current submission guidelines. In general, documents to submit in order to maximize insurance fee reimbursement include:

- X-rays of diagnostic quality
- Periodontal charting for osseous and other periodontal surgery procedures
- Explanation of benefits documents
- Photos
- Narratives

Coding

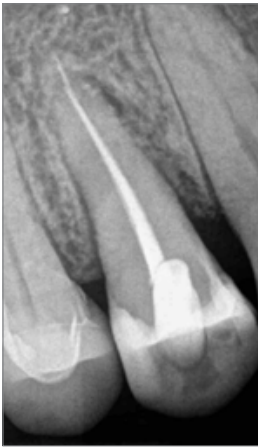- D7210 Surgical Removal of an Erupted Tooth
- D6104 Bone Graft at Time of Implant Placement
- D4266 Guided Tissue Regeneration - Resorbable Barrier
- D4267 Guided Tissue Regeneration - Nonresorbable Barrier
- D6190 Radiographic/Surgical Implant Index
- D6010 Surgical Placement of Implant Body
- D6051 Interim Abutment (Custom Healing Abutment)
- D6057 Custom Fabricated Abutment
- D6058 Abutment Supported Porcelain/Ceramic Crown
- D6065 Implant Supported Porcelain/Ceramic Crown

Implant Multilayer Restoration on Tooth #5 with VITA ENAMIC® IS Abutment and VITABLOCS® TriLuxe forte Crown

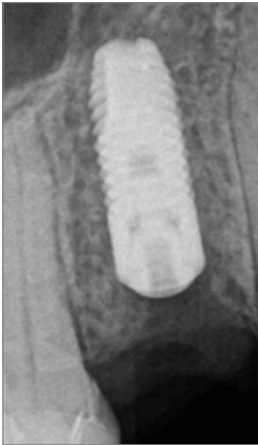Daniel Buttermann, DDS – Centennial, CO

Patient Presentation

The patient is a 52-year-old female with an unremarkable medical history. She presented with spontaneous pain and was unable to put pressure on tooth #5 due to a root fracture. The tooth was extracted and the site was grafted with a cortico/cancellous allograft mix. The site was allowed to heal for three months and subsequently an Astra 4.1 X 10 implant was placed and allowed to integrate for 12 weeks.



Patient presented a root fracture on tooth #5.

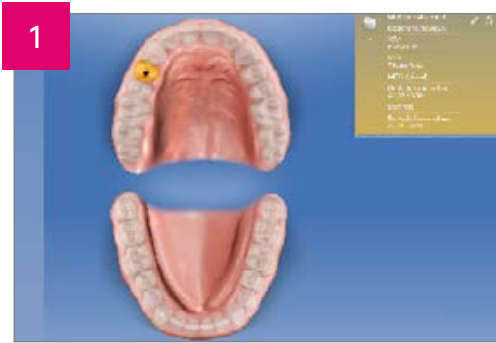


Implant after 12 weeks of integration.

Armamentarium

- Chairside CAD/CAM system
- Scan post and scan body to image the implant platform, angulation and timing into the CAD/CAM system.
- TiBase specific to the implant connection and platform diameter.
- VITA ENAMIC IS size 14 L in shade 1M2
- VITABLOCS TriLuxe forte in shade 1M2C
- Multilink hybrid abutment cement to join the abutment to the TiBase.
- Hydrofluoric acid for etching
- Silane for intaglio surface of restorations
- VITA Easyshade V
- VITA ENAMIC Stains Kit
- Curing light

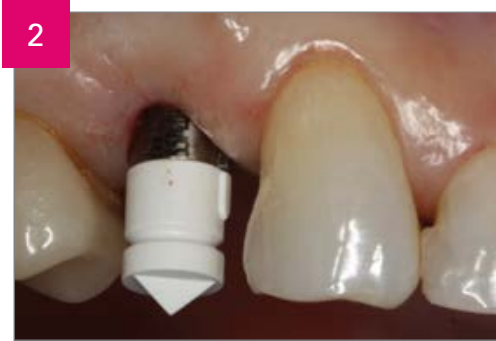Administration



Always set up as multilayer restoration, even if you plan on a screw-retained restoration.

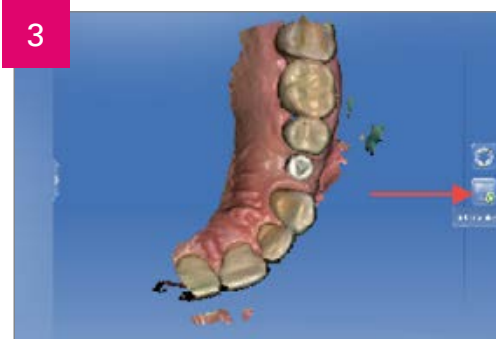- Select VITA ENAMIC IS as the abutment material.
- Select VITABLOCS TriLuxe forte as the veneering material.
- Select the appropriate TiBase for implant brand and platform size.
- Always use a scan post to image the implant platform and timing.

Imaging



Tips:

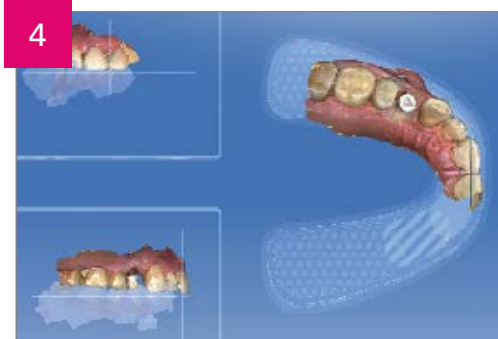
- Make sure the scan post is fully seated on the implant and verify with an X-ray.
- For a screw-retained crown, it is best to place the scan post notch interproximally because the sprue will mill 90 degrees from the notch. For an abutment, notch position is not an issue because the software will position it using different criteria.
- Make sure scan body is correctly seated over notch of scan post.
- The shiny scan post may be difficult to scan. Focus on scanning the area where the scan post meets the gingiva. If you do not have enough scanned data, the software may assume the scan post is an artifact and remove it from the image.
- Before dismissing the patient, always move forward to making the models step to confirm that all imaging is accurate.



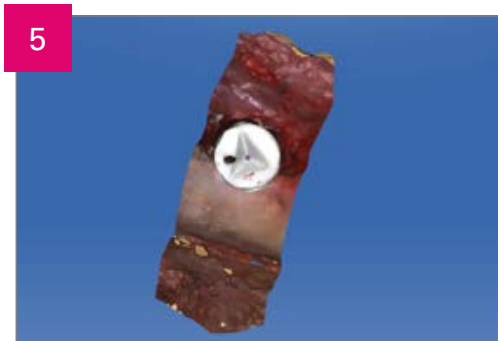
Steps:

- Add gingival mask catalog.
- Remove healing abutment and scan gingiva. Be sure to catch the contacts of the adjacent teeth as this will be more difficult to accomplish once the scan post is placed.
- Scan opposing arch and buccal bite.
- Copy gingival mask scan to the restoration catalog (upper or lower arch).
- Use the Cut Tool to remove a small area around the implant.
- Place scan post and image just enough to fully fill in the scan post data.
- Verify stitch of gingival mask, move forward to models and dismiss patient, or continue with restoration if doing in a single visit.

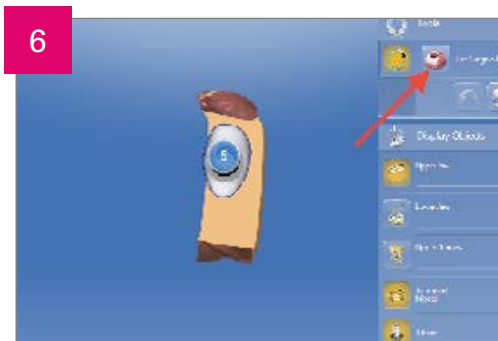
Design



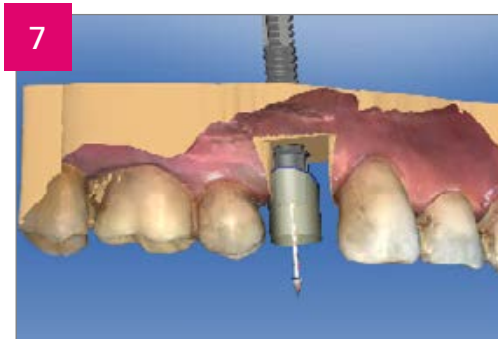
Set the model axis.



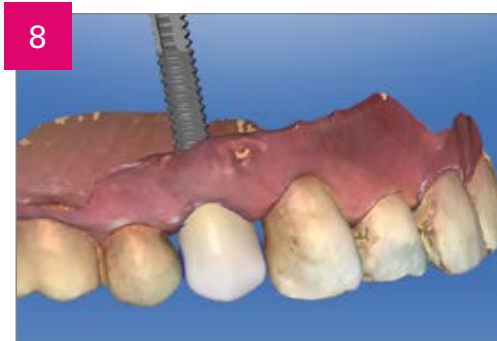Trim model and click on scan body head.



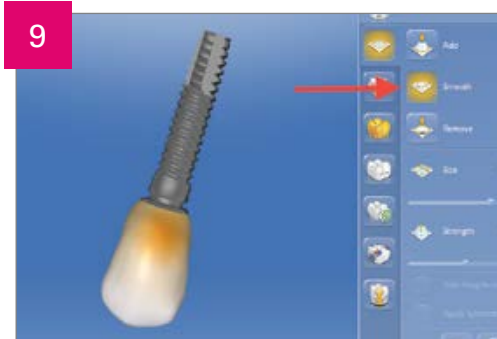
Uncheck "use gingiva mask" unless the tissue has been well sculpted for the restoration.



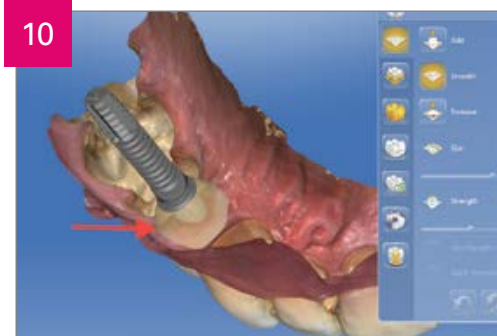
Verify path of insertion and abutment angle.



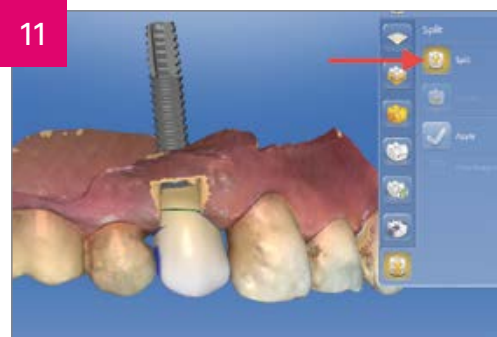
Design full contour restoration as usual, for the moment ignoring the sub-gingival areas (restoration thickness, contour, occlusion, contacts).



Under display, remove the model arch that you are working on, and adjust the emergence and contours of the sub-gingival areas so that they are smooth and flowing.

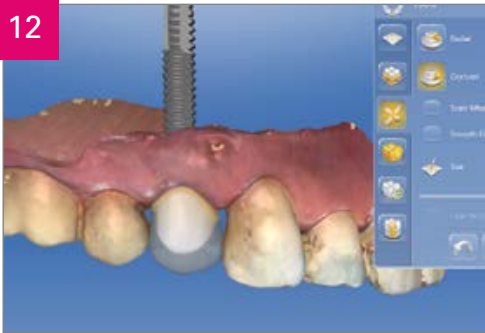

Turn on the gingiva mask folder and make the restoration slightly translucent to evaluate the amount of pressure that will be placed on the tissue. Any white restoration show-through will be pressure on the tissue. Any tissue show-through will be a void. If there is too much tissue pressure, it may be necessary to do a mid-crestal incision at delivery. When placing, my rule of thumb is that any blanching should subside within approximately 5 minutes.



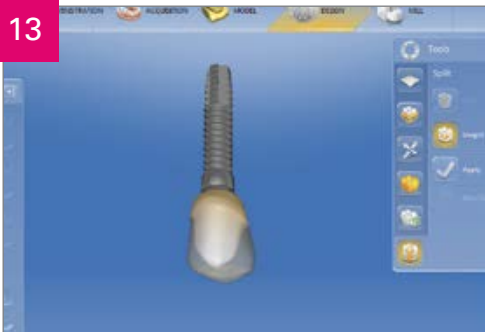Use the split tool to make the restoration multilayer.

12




Use the scale occlusal tool to hide the abutment margin subgingivally.

13



VITA ENAMIC 14L in shade 1M2 is used to mill the abutment.

14



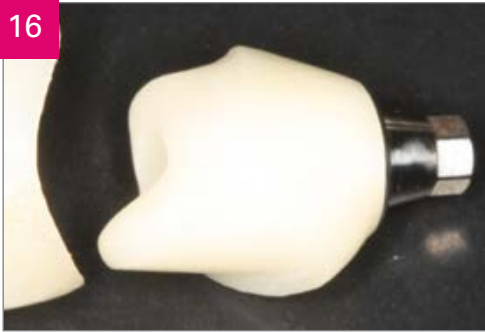VITABLOCS TriLux forte in shade 1M2C is used to mill the crown.

15



The abutment milled in 16 minutes and the crown milled in 8 minutes, for a total mill time of 24 minutes.

16



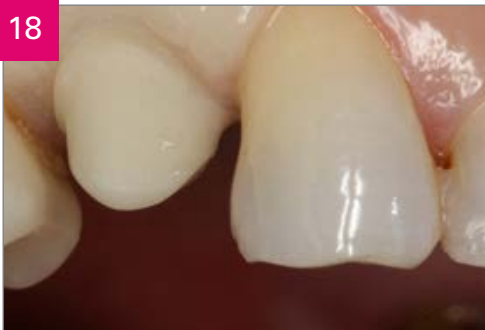Bond the finished VITA ENAMIC IS abutment to the TiBase. Refer to the Appendix section titled **Bonding to TiBase** at the end of this workbook for the proper protocol.

17



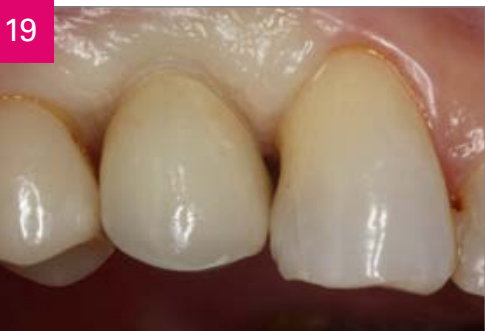Note the excellent marginal fit to the TiBase collar.

18



Prior to placing the abutment in the mouth, both the abutment and the intaglio of the crown were treated with hydrofluoric acid 5% for 60 seconds. Silane was then applied to both surfaces. The abutment was torqued into place and the screw access hole was sealed with Teflon and composite.

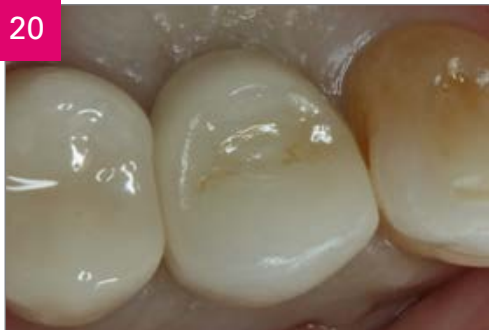19



Once the abutment was torqued to the implant and Teflon placed in the screw access hole, the VITABLOCS TriLux forte crown was bonded onto the abutment with RelyX Ultimate cement.

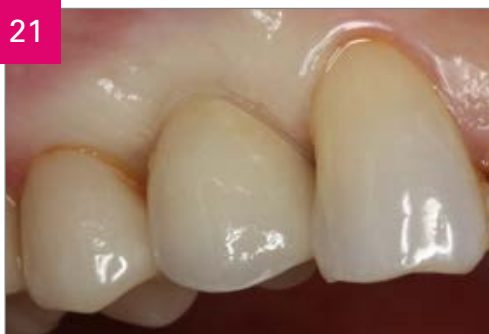Result

20



The contours of the final restoration and long broad contacts will prevent food impaction and help keep the gingiva healthy.

21



The finished result immediate post-op shows excellent fit and shade match.

This case was done as a multilayer restoration to take advantage of VITABLOCS TriLuxe forte's translucency in order to match the adjacent canine. If any gingival recession should occur years down the road, the perfectly matched VITA ENAMIC abutment color will look like recession around a natural tooth.

U. S. Insurance

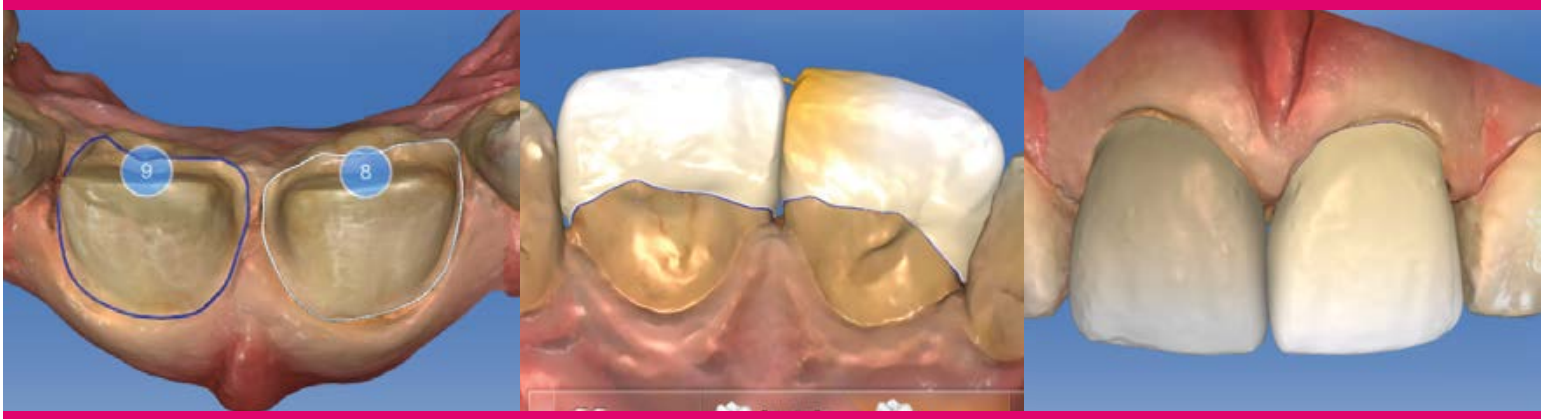
Always consult with the insurance provider for current submission guidelines. In general, documents to submit in order to maximize insurance fee reimbursement include:

- X-rays of diagnostic quality
- Periodontal charting for osseous and other periodontal surgery procedures
- Explanation of benefits documents
- Photos
- Narratives

Coding

D7210	Surgical Removal of an Erupted Tooth
D6104	Bone Graft at Time of Implant Placement
D4266	Guided Tissue Regeneration - Resorbable Barrier
D4267	Guided Tissue Regeneration - Nonresorbable Barrier
D6190	Radiographic/Surgical Implant Index
D6010	Surgical Placement of Implant Body
D6051	Interim Abutment (Custom Healing Abutment)
D6057	Custom Fabricated Abutment
D6058	Abutment Supported Porcelain/Ceramic Crown
D6065	Implant Supported Porcelain/Ceramic Crown

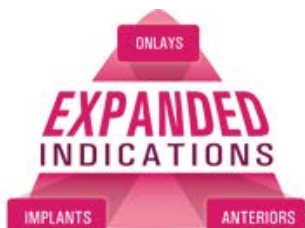EXPANDED



INDICATIONS

Section 2: Anterior Restorations

Restorative Process for Anterior Esthetics



VITA

Clinical Considerations

Patient Consultation

Understanding Patient Needs and Setting Expectations

Anterior ceramic restorations are unique in that they can be classified into two distinct categories: need versus want. That is, sometimes patients need anterior crowns or veneers to restore function, treat defective restorations or decay, or restore broken tooth structure. However, there are other instances in which patients seek out elective dental care to improve their overall smile. In either instance, an appropriate plan has to be set in motion to ensure that the patient's expectations are met, but also that the restorations last as long as possible.

Conservation of tooth structure is always the most critical parameter for both anterior restoration esthetics and longevity.

Questions to consider during the diagnostic process:

- Are restorations needed at all or is another treatment like orthodontics a better option?
- If restorations are needed, how much tooth structure will need to be removed?
- If restorations are needed, would orthodontics reduce the amount of tooth structure that needs to be removed?
- Can the occlusion be managed with the restorations?
- Is the gingival architecture acceptable?

Once all these questions are addressed in a systematic approach, only then can we decide what treatment is most acceptable to meet the patient's needs and expectations.

Treatment Planning

Imaging

The treatment planning conversation will always start first with conservation of tooth structure; the concept of "less is more". Based on the patient's values, budget, and overall goal of treatment, a plan will be developed. Sometimes the plan is not ideal and those potential compromises (both esthetically and functionally) will be discussed with the patient before getting consent to do the treatment.

Once the patient is ready to move forward, planning is critical to success. Depending on the complexity of the case, this planning could involve:

- Digital mockup (smile design)
- Composite mockup
- Diagnostic waxup
- Any combination of the three

It is important to have an idea of where you are going before you start. It will also help determine potential limitations or concerns of the treatment that have been accepted.

Replacing Discolored Ceramic Veneer Centrals with VITABLOCS® TriLuxe

Michael Skramstad DDS – Orono, Minnesota

Material Selection

Function and Esthetics

When choosing materials for anterior restorations, esthetics is always the number one goal. Esthetics is going to be a function of material translucence, material thickness and maintaining natural optical properties. The two most important optical properties to create esthetics are translucence and value. When looking at the optical properties of enamel and dentin, the translucence and value are both located in the enamel. This leads to two very simple esthetic rules:

1. If you remove all the enamel you remove the two most important optical properties for esthetics.
2. There are diminishing returns for excessive restoration thickness

Therefore, when restoring teeth with monolithic materials, the more a tooth is reduced, the more the value will drop and the less natural the restoration will be. In cases where occlusion is controlled and esthetics can be valued over strength, VITA feldspathic blocks have many advantages over other materials. Some of those advantages include the following:

- VITABLOCS can be milled very thin
- VITA feldspathic ceramic has a very “natural” value to it
- Multicolored blocks like VITABLOCS TriLuxe and VITABLOCS TriLuxe forte give us multiple options to control both the incisal translucency and cervical chromaticity of the restoration
- The shade of the block can be evaluated immediately after milling the restoration

How I decide between VITABLOCS Mark II, TriLuxe and TriLuxe forte is determined by how much incisal translucency and cervical chroma the restoration needs. VITABLOCS TriLuxe has a larger zone of incisal translucency than VITABLOCS TriLuxe forte, and VITABLOCS TriLuxe forte has the ability to give more cervical chroma than VITABLOCS TriLuxe.

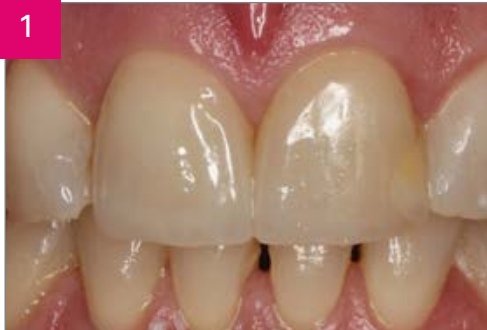Armamentarium

- Chairside CAD/CAM system
- Dr. Bob Winter's Restorative Design Kit (Brasseler USA - pictured). *The most important aspect of this kit is the facial reduction burs. These allow you to control the facial reduction to maximize enamel for esthetics.*
- 3M® Soflex disks for final smoothing of preparation
- VITABLOCS TriLuxe in shade 1M2C
- VITA Easyshade V
- Cerecdotors.com finishing kit (Meisinger USA)
- DiaShine Coarse soft finishing paste (VH Technologies)
- VITA staining and glazing pins
- VITA Firing Paste to hold the restorations on the pin
- VITA Akzent Plus staining and glazing kit
- Furnace to fire the restorations
- Ceramic HF acid etch
- Ceramic Silane for intaglio of restoration
- Bonding agent and resin
- Curing light



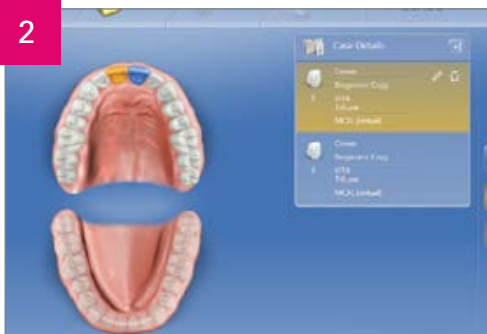
Replacing Discolored Ceramic Veneer Centrals with **VITABLOCS® TriLuxe**

1



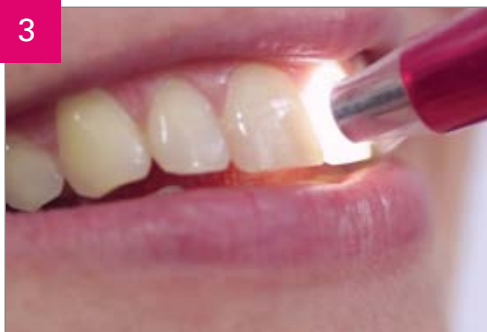This patient presents ceramic veneers that need replacement on tooth #8 and #9.

2



On the Administration screen, designate the restorations as Crowns -> Biogeneric Copy (copy the shape of the original veneers), VITABLOCS TriLuxe or VITABLOCS TriLuxe forte. VITABLOCS TriLuxe was used in this case due to its large zone of incisal translucency.

3



Utilize the VITA Easyshade V to determine the final VITA classical A1–D4 and VITA SYSTEM 3D-MASTER shade. This will guide you to the correct VITABLOCS shade to use in the “Block Mode” shade display.

4

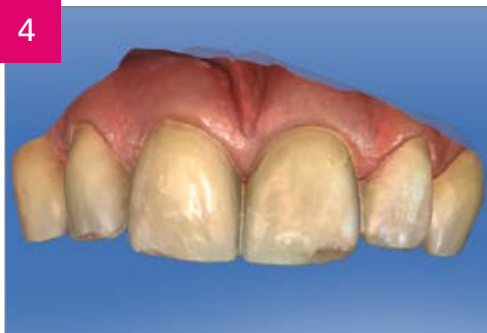
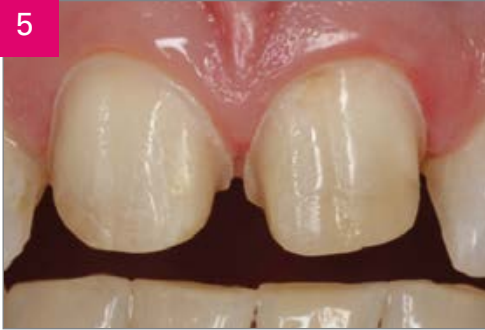
Image the preop (Biocopy) of the original veneers.

5



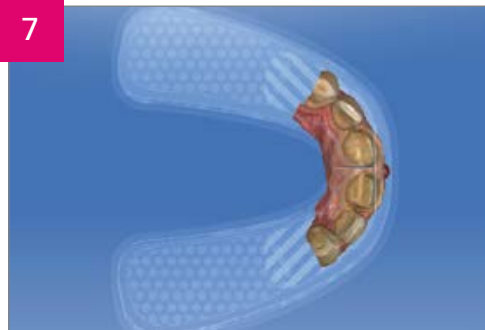
Prep the teeth. The veneer preparations were extended to $\frac{3}{4}$ crowns due to interproximal decay. The lingual margins were located above the gingulum.

6

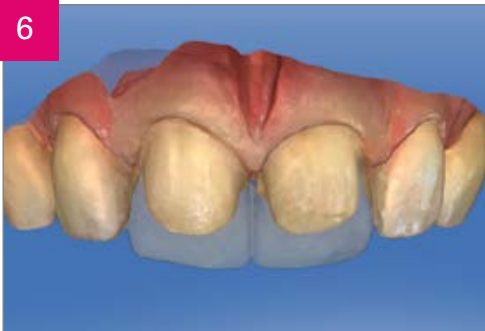

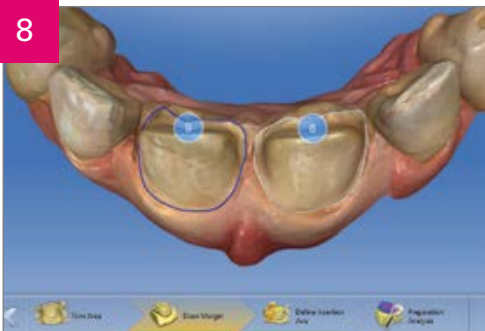
Image the final preparations and verify that the Biocopy and Preparation stitch properly.

7



Align the model axis properly so that the Curve of Spee and Curve of Wilson are correct.

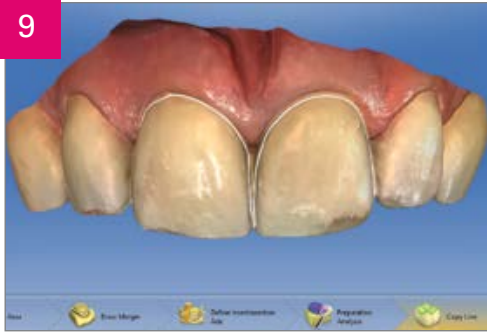8



Marginate the preparations.

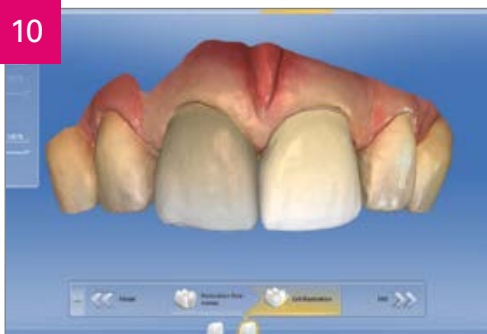Replacing Discolored Ceramic Veneer Centrals with VITABLOCS® TriLuxe

9



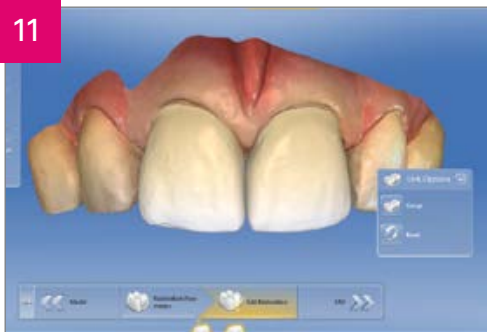Draw the copy lines on the preoperative veneers to copy the entire preop veneer contours.

10



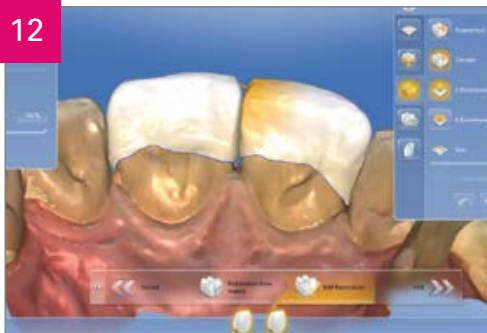The initial proposals should reflect the exact contours of the preexisting condition.

11



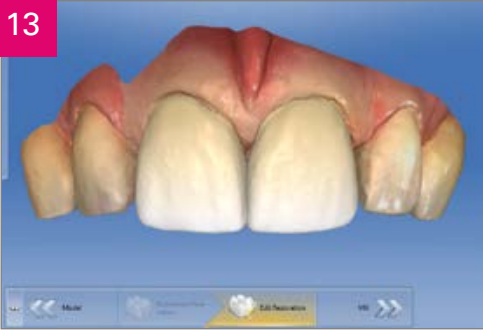Once you have symmetry with the existing proposals, it is important to open up link options on the right side bar and group the restorations together symmetrically. If you continue to design one tooth at a time with the tools, you can lose the symmetry of the central incisors, which is very important to maintain.

12



The most important part of the design is to use a two-directional circular shape to symmetrically close the midline from the lingual aspect of the restorations. This maintains the facial shape of the tooth. If you close the midline facial to the contact area, you lose the “triangular” shape of the tooth and it becomes a little more square and wide.

13



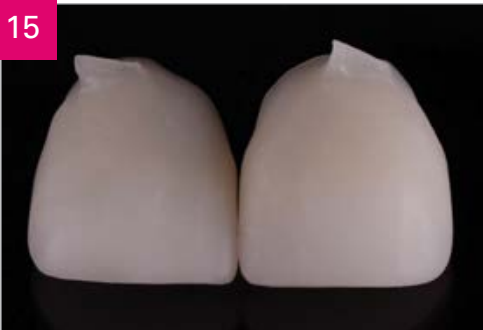The final design of the restorations.

14



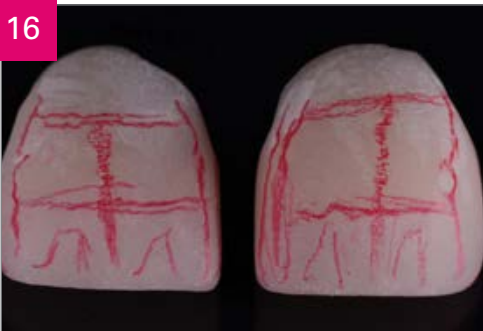
When using VITABLOCS TriLuxe or TriLuxe forte, you can position the restoration within the block to help guide how much incisal translucency and chroma you would like with the final restorations.

15



Final milled restorations in VITABLOCS TriLuxe right out of the milling chamber. No firing is needed and we can move directly to final contouring. Milling time is about 12 minutes per crown.

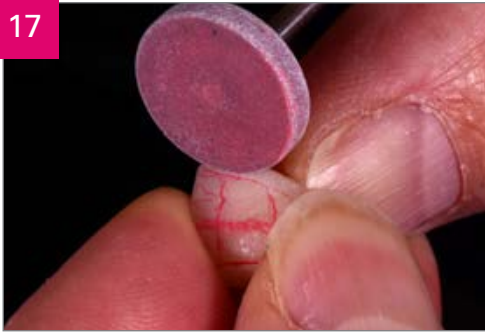16



The milled restorations lack defined anatomy and line angles, the first step after milling is to use a red pencil to define the areas you would like to accentuate and define.


Replacing Discolored Ceramic Veneer Centrals with **VITABLOCS® TriLuxe**

17



Major contouring of the line angles is done with a heatless pink stone (The cerecdoctors.com Finishing Kit).

18



Contouring of the anatomy and other defining characteristics of the crown is done with a large diamond (The cerecdoctors.com Finishing Kit) in a slow speed electric handpiece.

19



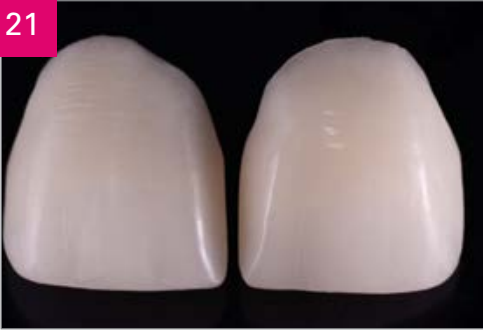Removal of all diamond bur marks from milling and contouring is done with a green Meisinger Twist Polisher (The cerecdoctors.com Finishing Kit).

20



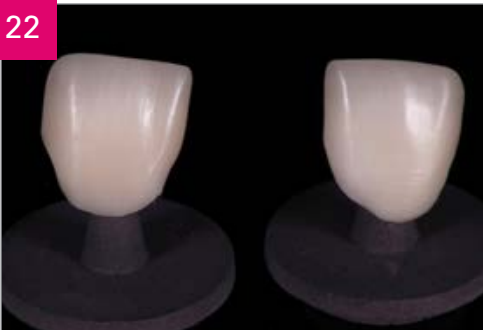
A DiaShine Coarse Soft wheel is then used to remove surface tension from the restorations and prepare it for staining and glazing.

21



The restorations are now ready for staining and glazing.

22



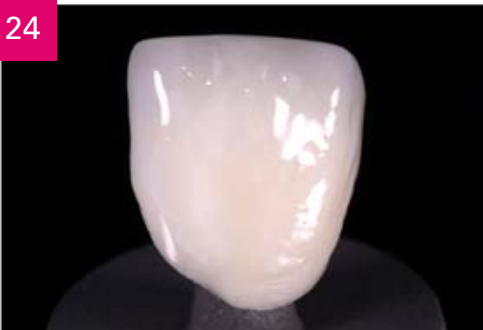The restorations are placed on VITA firing pins with VITA Firing Paste to properly stabilize and prepare them for staining and glazing.

23



A very fine layer of VITA AKZENT PLUS LT low-temp glaze is placed on the restorations.

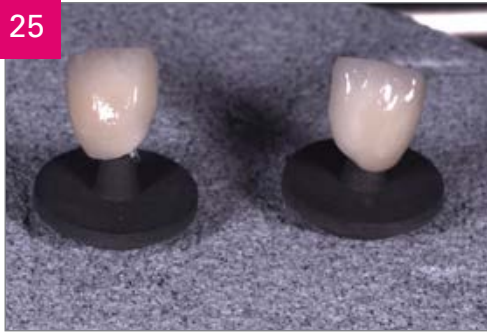24



Appropriate stains are then added to the restorations to match existing characteristics of the adjacent teeth. In this case, a little bit of white and blue are added to create translucency, particularly on the incisal edge.

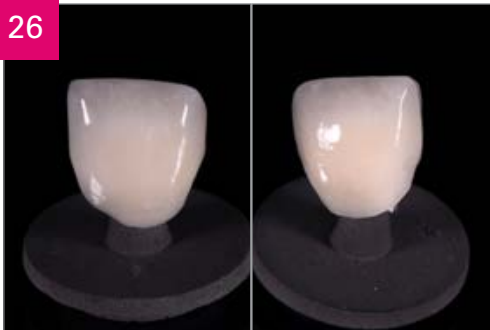Replacing Discolored Ceramic Veneer Centrals with **VITABLOCS® TriLuxe**

25




The restorations are then placed in the VITA VACUMAT 6000 M furnace for firing of the stains and glazes. Firing time is approximately 10 minutes.

26



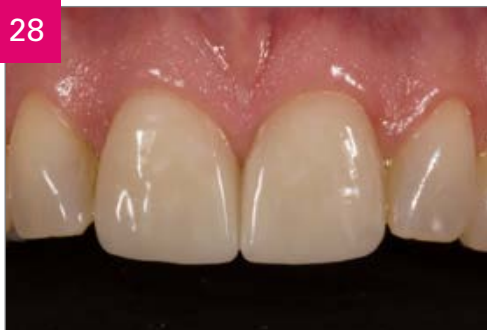Final stained and glazed restorations immediately out of the furnace.

27



Since the restorations come out of the furnace a little shiny from the glaze, it is recommended that you polish the glaze afterwards. Either the pink Meisinger Twist Polisher or the Diashine Coarse Soft from The cerecdotors.com Finishing Kit can be used to dull the restorations to a more natural finish.

28



Final restorations bonded in the mouth. You can see how VITA feldspathic porcelain does an excellent job delivering a natural and esthetic final result.

Result

As a rule, the final result of anterior cosmetic cases is a result of three deeply interconnected concepts:

1. Controlling the preparation to maximize the natural optical properties of the tooth
2. Material selection to maximize translucency and correct value
3. Contouring the restoration to maximize light reflection and natural luster

When these three aspects are controlled, the chances of meeting the patient's clinical expectations are greatly increased. Using VITABLOCS feldspathic porcelain gives you the ability to control different aspects of chroma and translucency via the multicolored blocks (VITABLOCS TriLuxe and VITABLOCS TriLuxe forte). All this results in a happy patient, which is the overall goal of treatment.

U.S. Insurance

It is always a good idea to pre-authorize anterior crowns whenever possible in order to provide the patient with accurate insurance benefit information.

Always consult with the insurance provider for current submission guidelines. In general, documents to submit in order to maximize insurance fee reimbursement include:

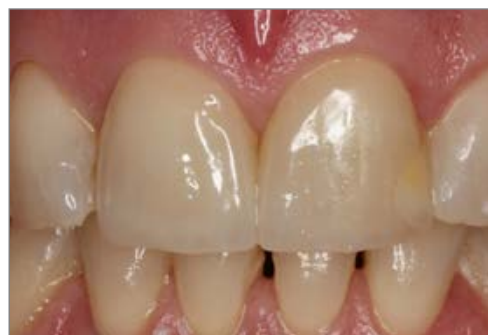- X-rays of diagnostic quality
- Explanation of benefits documents
- Photos
- Narrative stating the surfaces of the tooth/teeth that are fractured, have decay, or have failing restorations.

Coding

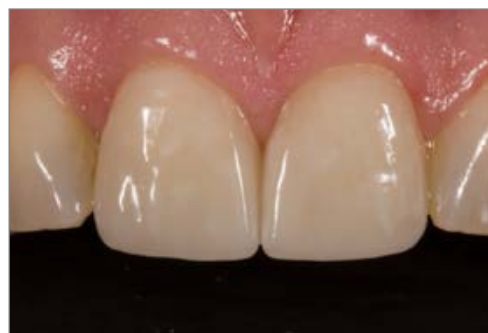D2740 Porcelain crown

D2783 3/4 porcelain crown; Involves mesial, facial, and distal while the lingual surface remains intact. This is usually reimbursed by insurance.

D2962 Labial porcelain veneer; Extends interproximally and/or covers the incisal edge. This is not usually covered by insurance.

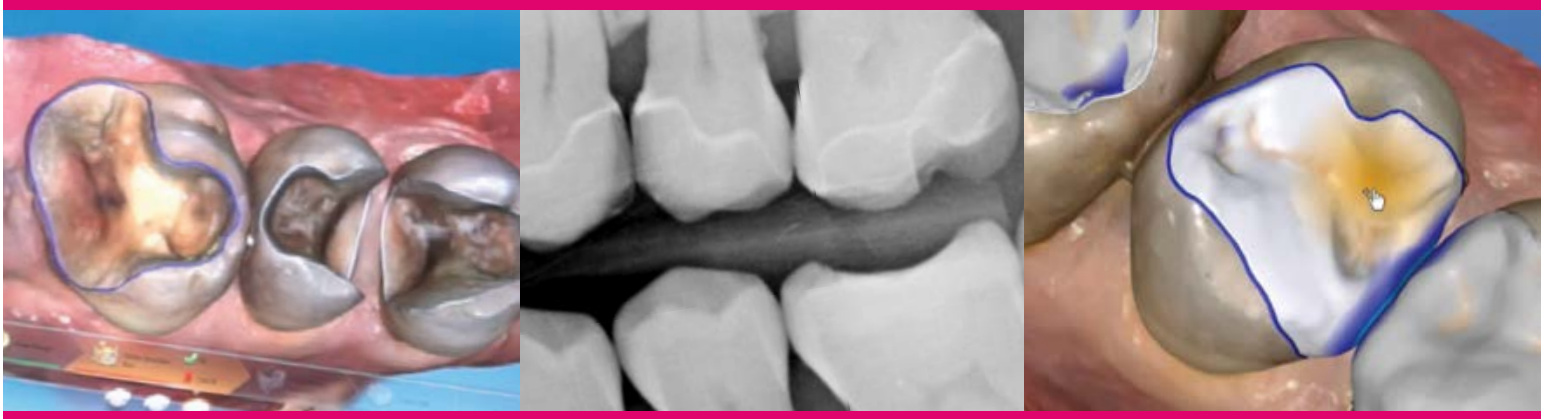

Before



After

EXPANDED



INDICATIONS

Section 3: Onlays

Restorative and Insurance Reimbursement
Process for Onlay Solutions



VITA

Clinical Considerations

Patient Consultation

Understanding Patient Needs and Setting Expectations

When a patient presents, the goal should be to do everything possible to avoid a crown and perform a more conservative procedure. Saving tooth structure while restoring the pathological portions of the tooth is the ultimate objective for a partial coverage restoration. This releases the anxiety and pressure the patient may feel, and allows the doctor and patient to have an open dialogue about the treatment plan.

While we have fantastic restorative materials, they are not a pure exchange for dentin and enamel. Therefore, while removing a large carious lesion or preparing a fractured cusp, the clinician needs to actively think about the tooth structure that should remain.

It is imperative to take the right images of the patient's teeth so they can see a clear visual of all the affected areas. Intraoral and quadrant images will equally show what is good and bad, allowing the patient to view the entire arch of teeth that are impacted. Proper documentation is also essential to maximize treatment fees and insurance reimbursement.

Questions to consider during the diagnostic process:

- Is the patient a good candidate for a partial coverage (onlay) restoration?
- Does the patient have cracked tooth syndrome? If so, full coverage crown restorations are required.
- Have we treated this patient before? If so, can we prevent the patient from having to repeat certain procedures on other teeth by proactively treating them?
- Once we have examined and removed the dental caries, can we proceed with an onlay? If the condition warrants full cuspal coverage, we can determine to proceed with a crown at that time.

Treatment Planning

Varying philosophies and clinical experiences lead to strong opinions regarding the pros and cons of onlay restorations. With this said, chairside CAD/CAM systems can greatly change one's view on the success of onlays. This is because the frustration and difficulties of a temporary restoration are removed. Being able to skip this step and go straight to the final restoration makes it easier to accomplish the restoration and save tooth structure. There are many philosophies regarding what should stay and what should be removed.

There are no right or wrong answers, just a willingness to err on a conservative approach to tooth removal.

Amalgam restorations can teach us a lot about what tooth structure is able to withstand. For instance, a large MOD amalgam restoration may be next to small remnants of cusps, but they seem to be successful for many years. If we were to keep that in mind as we are preparing a tooth, we may be more willing to bond a ceramic restoration of the same size and margin position. However, we do not necessarily need to keep the mechanical resistance and retention form requirements that gold requires, but we mistakenly go down that path. Bonding enamel and dentin with resin has been clinically successful and predictable since fourth generation bonding. The problem is that clinicians may still use gold onlay design requirements for ceramics, which is not necessary. Sometimes it is difficult for the clinician to decide whether a tooth's restoration could be completed with an onlay. Onlay treatment planning takes careful thought of what tooth structure can stay and what should not, but is often just as efficient as performing a direct restoration.

Preparation Design

The following are some considerations for preparation design for CAD/CAM restorations:

1. Occlusal reduction

Adequate occlusal reduction is necessary for longevity and to provide adequate material thickness to withstand occlusal forces.

2. Occlusal isthmus

In the same regard as occlusal reduction for bulk, the occlusal isthmus should also be considered. The inlay component should obviously be larger than what a sealant would be over a fissure. A minimum of 1 mm (VITA ENAMIC, VITABLOCS 1.5 mm) of occlusal isthmus should be made. This is considering the limitations of machining of the ceramic and internal flexure of the tooth.

3. Exit angles

The angle for which the cavosurface margin exits to the outer surface of the tooth should be as close to 90 degrees as possible. The blunt surface allows for thicker ceramic butted up to a flat surface of tooth structure.

4. Interproximal margins

It is always easiest for a restoration to be made when the interproximal contacts are opened. This is also most likely where interproximal caries occurs.

5. Buccal and lingual margins

Keep them high and dry. Unless esthetic concerns dictate, buccal and lingual margins can be placed anywhere along their surfaces, as long as adequate occlusal reduction is achieved. One technique places the margin just above or at the height of contour where the enamel is the thickest. This margin will give increased surface area of enamel for predictable bonding.

6. Round, round, round

As the preparation is made, smooth transitions should be made. This not only includes the cavosurface margin, but the internal surfaces as well.

Imaging and Documentation

Pre-operational images are imperative in making a proper diagnosis. The number of images is not significant, but taking the right types of images is an important factor. Intraoral and quadrant images that reveal the size of the restoration, and the pathology of the affected teeth, as well as a good visual of the adjacent teeth, is the goal.

Types of Restorations

There are two types of restorations: partial coverage restorations, or onlays, and full coverage restorations, or crowns.

Material Selection

Function and Esthetics

Ideally, the goal is to use a material that ensures longevity and good wear. For long-lasting partial and full coverage restorations, the materials must bend and flex within the tooth itself. VITA ENAMIC does this extremely well and is also repairable. If only a small portion of the tooth needs treatment, like recurrent caries at the margin, you can rebond to the original material. VITA ENAMIC closely resembles the characteristics of a natural tooth and looks esthetically pleasing. The material also has the right balance of abrasion resistance to adjacent teeth.

Economics

With VITA ENAMIC, there is less tooth reduction and less iatrogenic damage to the tooth, making the restoration process much simpler and quicker. Imagine taking out the amalgam, removing the caries, and following the outline that is left for the onlay. This can be completed very quickly after the amalgam is removed and faster than a build-up is completed for a crown preparation. It is also just as efficient as a simple direct restoration.

Replacing Metal Fillings with Milled VITA ENAMIC® Onlays

Todd Ehrlich, DDS, FAGD – Austin, TX

Patient Presentation

The patient, in his mid-50's, asked me to systematically replace his metal fillings after we removed an amalgam restoration. At that appointment, we demonstrated that there was tremendous "leakage" under his restoration, and he deduced that the rest of them were probably in the same condition. He was, of course, correct, and we were not in that difficult situation of "selling" a patient on treatment.

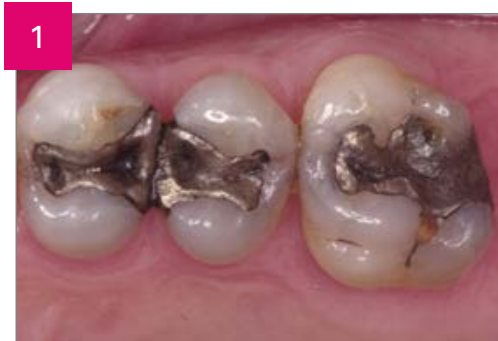We all have many patients that lived the "extension for prevention" time of dentistry and have large amalgams that are 20-plus years old. While that philosophy was sound at the time, it was hard to imagine what was the NEXT step for these teeth. What was going to be the next chapter? There was no way of knowing then the kind of technology we would have today. I applaud amalgam and its longevity, durability and ease of placement. It has saved countless numbers of teeth even in compromised situations. However, today's ceramics and bonding techniques, in my opinion, greatly advance the restoration style over a directly placed amalgam. There are those that will beg to differ. This is understandable, but today's amalgams are not any better than they were 30 years ago. What will that fresh amalgam today look like 15-20 years from now? What if the ceramic fails to recurrent caries or fracture at the same time? At least it will be caught a lot sooner than a radio-opaque amalgam with recurrent caries amassing under the restoration.

When a patient is able to understand what happens under these amalgams over time, it is quite natural for them to accept treatment. The best way to make this happen is, of course, with excellent photography that shows the pathology.

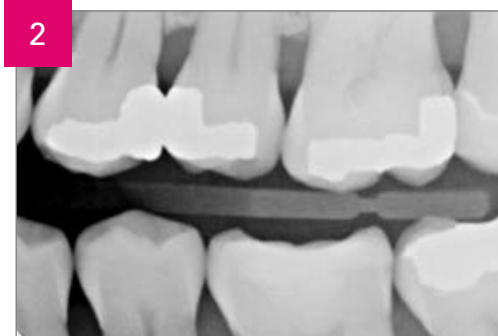Armamentarium

- Chairside CAD/CAM system
- VITA ENAMIC block shade 2M2 HT size 10
- Rubber dam or automatic saliva evacuation system
- Simple preparation bur block:
 - amalgam removal bur (diamond and/or carbide)
 - long divergent chamfer bur for general preparation
 - short divergent wide chamfer bur for easier access and making minimal occlusal isthmus diameter
 - long diamond flame bur to aid with exit angles
 - latch round bur for caries removal
- Caries indicator dye for assurance of complete caries removal
- VITA ENAMIC Polishing Set clinical and technical
- Hydrofluoric acid for etching VITA ENAMIC
- Silane for intaglio surface of restoration
- Low-film-thickness bonding agent properly placed and light cured
- Dual-cure resin cement system to allow light and chemical polymerization
- Curing light
- High-speed green stone point for cement removal and any occlusal adjustments
- Post-op x-ray to determine if any residual cement remains

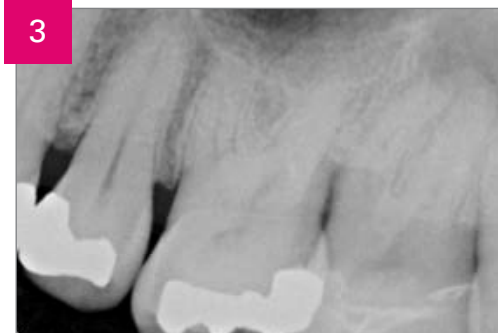Replacing Metal Fillings with Milled **VITA ENAMIC®** Onlays



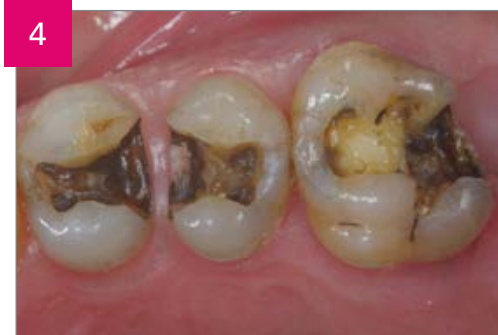No occlusion symptoms and a large remaining vertical enamel perimeter make this an excellent candidate for an onlay. Be sure to take preoperative photographs...



...and preoperative bitewing – both will be needed for insurance considerations and patient education.



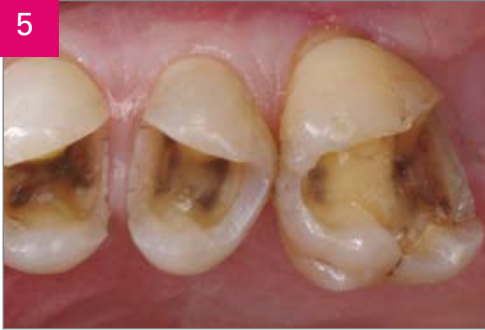A preoperative periapical should also be captured.



If present, remove existing amalgam and leave any pathology present for photographs. After amalgams are removed, it is easy to assume that cusps are now “undermined” or “weak.” In reality, they have functioned next to recurrent caries for many years. Let the caries removal dictate the outline design first.

Take a picture for patient education and submission for insurance reimbursement.

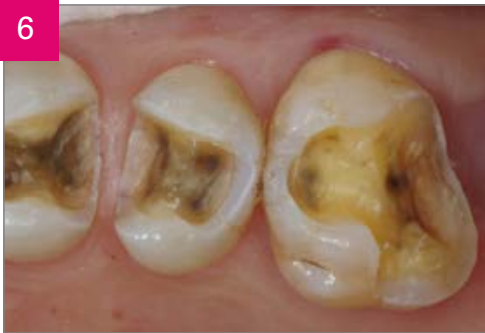5



Create prep in a conservative manner, accounting for adequate occlusal reduction, occlusal isthmus and exit angles.

Not all staining needs to be removed. With caries indicator stains, sound dentin can be found. Eliminating all staining could potentially endanger the health of the pulp unnecessarily.

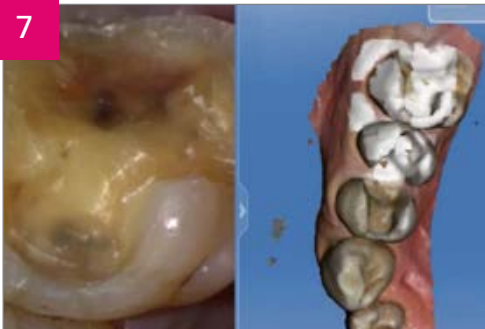
6



When a fracture line under a cusp is seen while removing caries, the clinical decision must be made to keep or remove the cusp.

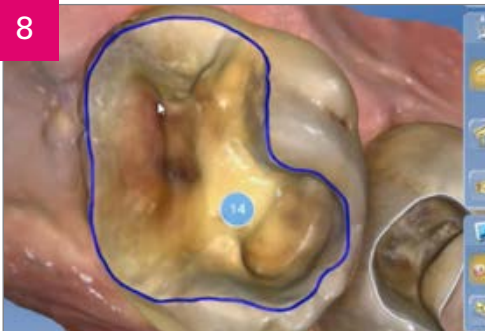In this case, the cusp was removed because of the position of the fracture under the functional cusp. Occlusal forces were slowly fracturing this cusp. Covering the cusp will limit propagation of the fracture.

7



Conduct digital imaging.

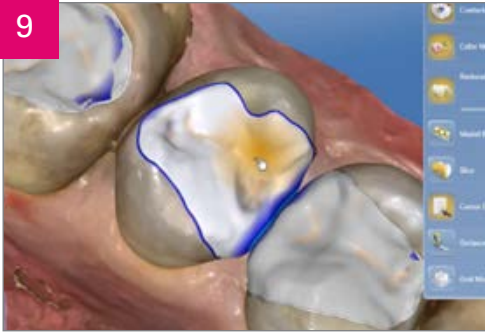
8



Mark the margins.

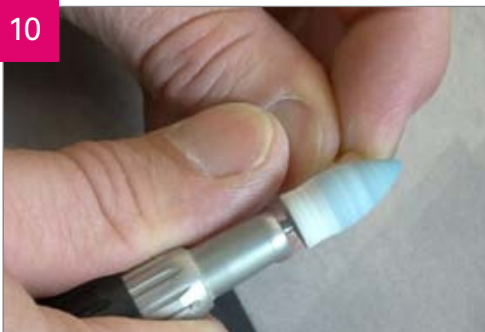Replacing Metal Fillings with Milled **VITA ENAMIC®** Onlays

9



Verify design proposal, adjust as needed and mill.

10



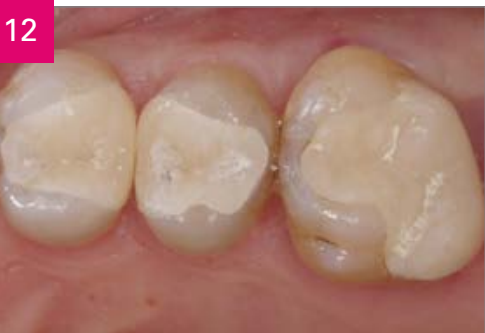Remove the sprue.

11



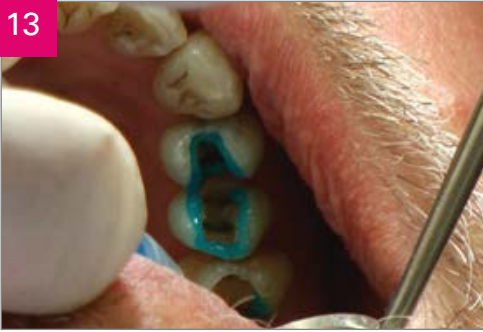Polish the restorations extraorally.

12



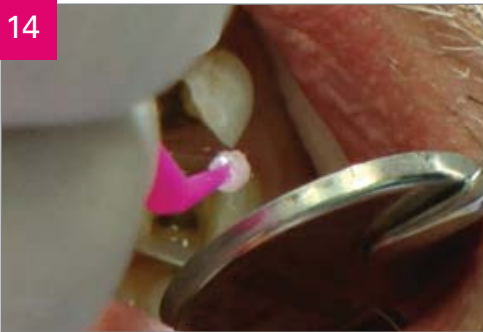Conduct an initial try-in to confirm fit and occlusion. During a dry try-in, most ceramics will appear opaque. After bonding with a resin cement they blend in much better.

13



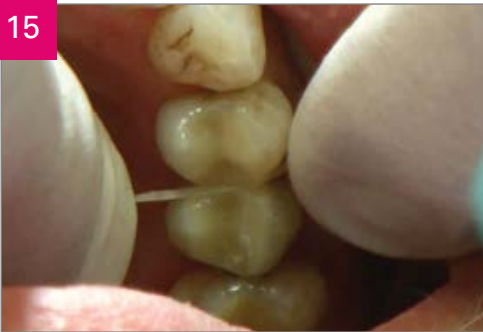Apply etch in preparation for bonding.
Refer to the Appendix section titled **Bonding to Tooth Structure** for complete directions.

14



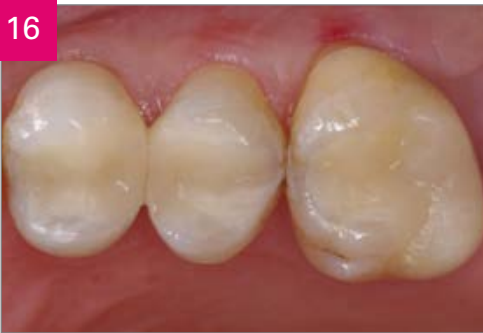Apply bonding agent per manufacturer's instructions.

15



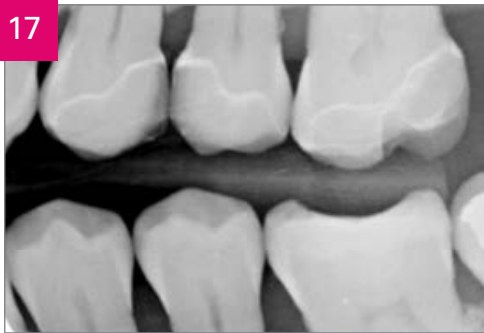Tack cure and floss through the contacts.
Complete the cure and polish.

16



Finished result. Note the blended margins and excellent shade match.

17



Document with a post-op bitewing.

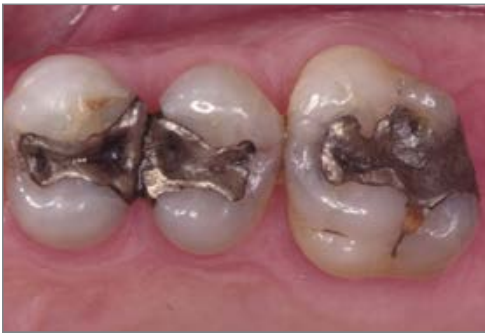Result

The results of this technique are very predictable. In fact, they are much more predictable than a matrix band and ring system. Think of this: How often have you taken off that direct composite ring and pulled out the matrix only to find an open/light contact, large areas of flash, high occlusion, poor contact size, or a bubble at the margin? With an indirect technique, these frustrations are greatly reduced, if non-existent. While they may take a little practice with preparation and cementation, onlays do not take much more than what it took to learn how to do direct composites!

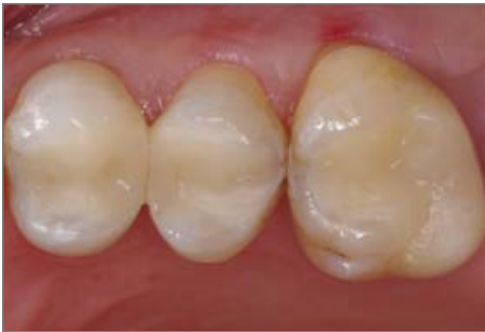Take the time to learn an indirect technique, be conservative of tooth structure, and build value for the restoration to the patient while doing so.

Clinical Expectations

The radiotranslucency of the bonded restoration has a major advantage: The clinician can see into it. All metal and zirconia restorations are radio opaque, making it much more difficult, if not impossible, to see recurrent caries. With VITA ENAMIC, if the slightest caries occurs, it will easily be picked up on a routine bite wing x-ray.



Before



After

Insurance Reimbursement

The dental insurance coverage should be confirmed before the procedure occurs. The insurance provider should be asked for its specific coverage of ceramic onlays and the codes that they cover. Providers may claim that they cover onlays but in reality, when submitted, they are sometimes downcoded to direct fillings. This is somewhat deceptive because they are covering those codes, but ultimately they may not because of a less costly alternative. Therefore, it is imperative that the restoration being submitted is utilizing an onlay code with proper documentation. Many insurance companies do not cover a two-surface onlay, which is unfortunate because there are many times where the restoration is very large on the occlusal-buccal surfaces, but does not incorporate the interproximal contacts. It is advisable to avoid the simple class II restorations to be submitted as an onlay (e.g., a mesio-occlusal onlay). An onlay covers a cusp, and therefore would be at minimum three surfaces – mesio-buccal-occlusal as in the documented case.

Proper documentation and coding are essential for maximum insurance reimbursement. In order to facilitate coverage for the procedure for the patient, it is imperative to prove the pathology. We no longer live in a time when the observations and opinions of the dentist carry as much weight as they did in prior decades, so it becomes more important to show the insurance provider appropriate x-rays and images of the clinical condition. For instance, a bitewing x-ray can show recurrent caries of an amalgam or incipient lesions really well, but a periapical x-ray is typically required for reimbursement of major procedures, like crowns and onlays. The periapical x-ray that goes with the insurance claim may be denied, or downcoded to another procedure. This can be extremely frustrating when a partial coverage restoration was indicated and the insurance company and its dentist advisors form their own opinion.

It is our duty to demonstrate that the pathology warranted an indirect restoration. When a dental consultant has the option of a direct restoration, like an amalgam, it will be downcoded because they can choose the less costly alternative. If it can be demonstrated that the indirect restoration was the only choice, and a crown was the only other alternative (rather than a direct filling), the chances of downcoding are very low.

A periapical x-ray leaves a lot of latitude in many cases to offer a differing opinion. We must facilitate the communication to the insurance consultant that the pathology of the tooth was significant enough that an indirect partial coverage restoration was warranted. This can easily be accomplished with three critical items:

- Pre-operative x-ray
- Pre-operative photograph
- Photograph(s) during the procedure

The photographs during the procedure should be done before the final preparation of the tooth. In other words, remove the prior restoration, or establish access to the caries, and then take the pictures. Many dentists will prepare the tooth as they are removing caries. While this may be efficient at the time of the appointment, it may keep you from being reimbursed.

Take pictures to prove the pathology, and then go to the final restorative preparation. Do not allow another clinician who was not part of the procedure to dictate what was in the best interest and well-being of the patient. Describe the clinical situation that is easily backed up with your pathology pictures.

Finished preparation pictures or pictures of the final restoration are not necessary; only pictures that show the problems. Many times a written narrative will enhance what the pictures demonstrate. The critical components of the narrative should demonstrate:

- Proper diagnosis, treatment planning and patient acceptance.
- A written discussion of the pathology. Make sure it is in correlation with the images taken.
- Discuss why a direct restoration would not be in the best interest and well-being of the patient.
- Research evidence that partial coverage restorations have a long-term success rate.
- An exclamation that the case not be downcoded without a personal discussion with the consultant personally.

The proper insurance codes to use for onlays that are typically reimbursed with proper documentation are:

D2643 Onlay – porcelain/ceramic – three surfaces

D2644 Onlay – porcelain/ceramic – four or more surfaces

Sample Insurance Letter

To Whom It May Concern,

I am enclosing this narrative to accompany our claim of insurance, radiograph, and intra-oral photograph of the teeth in need of treatment for (name). I have discussed the treatment options with the patient and we have decided that a bonded onlay was best due to strength, length of service, conservation of tooth structure, appearance, and cost. An over-aggressive crown would unnecessarily remove healthy tooth structure. A conservative, bonded onlay is a far superior choice for strength, durability, less cost, and less tooth reduction. This is in the best interest and well being of the patient. Potential reasons for an onlay are:

- 1) recurrent caries of the existing restoration,
- 2) undermined cusps – require onlay to support the dynamics of occlusion.
(AADC Positions Committee, Position Statement: Defining and Differentiating Inlays and Onlays, Feb. 6, 2008.)
- 3) The buccolingual width of the cavity is more than 1/2 the occlusal width.
(Christensen, GJ. Considering Tooth-colored Inlays and Onlays Versus Crowns. JADA 2008; 139 (5): 617-620.)
- 4) fracture of the mesial and/or distal marginal ridge,
- 5) horizontal fracture lines in a cusp.
(Christensen, GJ. Considering Tooth-colored Inlays and Onlays Versus Crowns. JADA 2008; 139 (5): 617-620.)

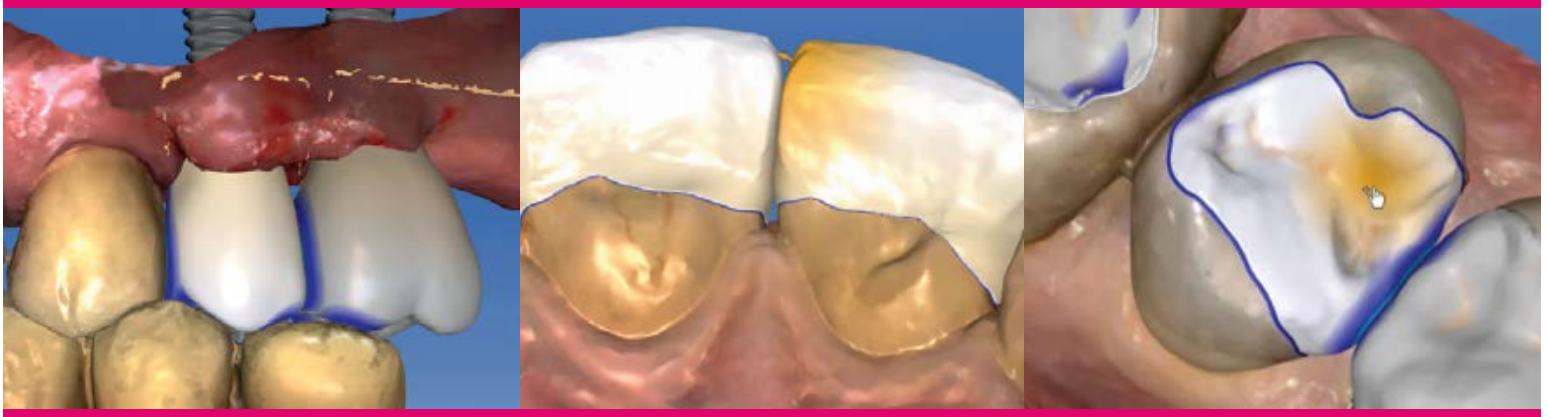
As illustrated above, the claimed teeth have the following:
(select from 1-5 above and add here)

For the reasons indicated above, a cast gold onlay, a cast gold crown, or a tooth reinforcing bonded onlay would be indicated as an acceptable restoration. The latter was chosen as the most effective and conservative treatment of predictable longevity. (Fracture Resistance of Different Partial Coverage Ceramic Molar Restorations. Stappert, C. JADA 2006; 137: 514-522.) (Longevity of 2328 chairside... inlays and onlays. Posselt, A & Kerschbaum T, 2003, Int J Computer Dent, 6(3): 231 - 248.)

If your plan does not identify the restoration by computer code, please consider paying the cast metal or crown equivalent. I request that you do not "downcode" this claim without notifying me personally. If any other information is needed, do not hesitate to contact me at (phone number).

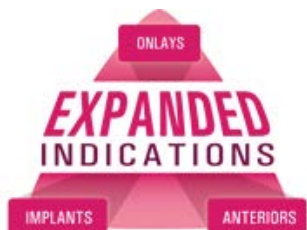Sincerely,

EXPANDED



INDICATIONS

APPENDIX



VITA

Shade Measurement

Clinical Shade Tips

- Shade determination should be carried out before preparation since, due to dehydration, the tooth shade can appear too white after preparation.
- Tooth shades should be determined in daylight or under standardized daylight lamps (e.g. Osram Lumilux® Deluxe daylight 12-950) and not under standard operatory lights.
- Make a swift selection; always accept your first decision, as eyes tire after 5-7 seconds.
- Avoid bright colors in the shade-taking environment; no lipstick, tinted eyeglasses or bright clothes.
- Rearranging the VITA classical shade tabs into Value order is popular among clinicians. This can be accomplished by arranging your tabs in this order:

B1, A1, B2, D2, A2, C1, C2, D4, A3, D3, A3, B3.5, B4, C3, A4, C4

VITA Manual Shade Systems

The VITA classical shade guide (A1–D4) is the globally recognized standard in dental shade measurement. While popular, the shade system makes producing intermediate shades difficult, as there is no uniform arrangement of the tabs in the dental color space.

The VITA SYSTEM 3D-MASTER shade system is recommended over the classical shade guide since shades are arranged in Value order from lightest to darkest. The system also provides a uniform distribution of shade tabs within the dental color space, making intermediate shades easy to produce.

Digital Shade Measurement

The VITA Easyshade V digital shade device instantly measures VITA classical and VITA SYSTEM 3D-MASTER shades and removes common causes of incorrect shade measure, like incorrect lighting and eye fatigue. The Easyshade V contains its own light source and utilizes multiple spectrometers to precisely measure and display tooth shade. The VITA Easyshade V also tracks bleaching progress, confirms shade match of restorative materials prior to seating, and displays the appropriate VITA CAD/CAM block for the restoration.




VITA Linearguide 3D-MASTER®



VITA Toothguide 3D-MASTER®



VITA Bleachedguide 3D-MASTER®



VITABLOCS Guide 3D-MASTER®



VITA classical A1–D4® with Bleached Shades



VITA Easyshade® V

Using the VITA Linearguide 3D-MASTER® Shade Guide

1



Remove the VITA Valueguide from the Linearguide.

2



Determine the lightness level (value)

Make a selection using the Valueguide, trusting the first instinct. This determines the level of lightness from 0 to 5.

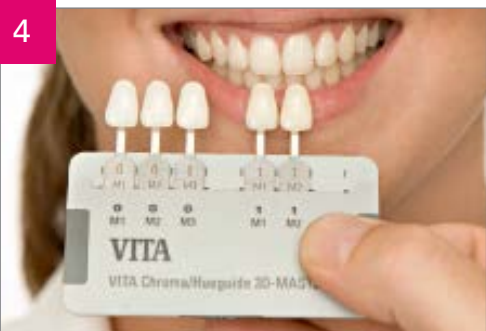3



Determine the Chroma/Hue

Remove the Chroma/Hueguide corresponding the Value level selected and make a definitive shade selection.

4



The correct tooth shade is now quickly and reliably selected.

VITABLOCS® Preparation Design



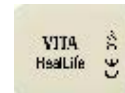
VITABLOCS Mark II



VITABLOCS TriLux

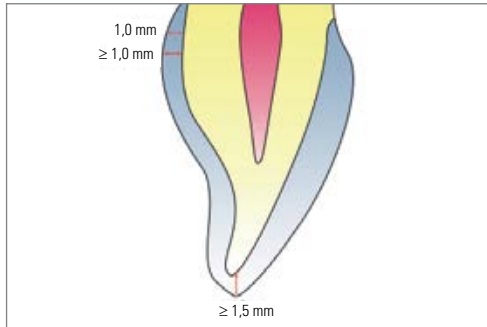


VITABLOCS TriLux forte



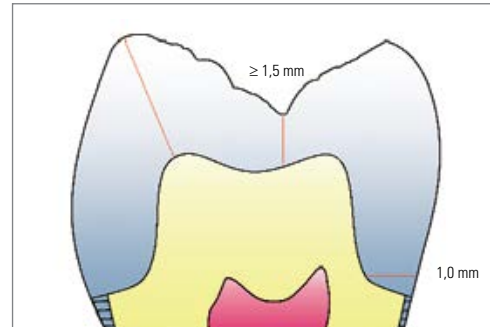
VITABLOCS RealLife

To ensure clinical success of restorations made from VITABLOCS, adhere to the following **minimum layer thickness** guidelines.
Acceptable margins: chamfer, accentuated chamfer, shoulder prep or step with rounded inner edge.



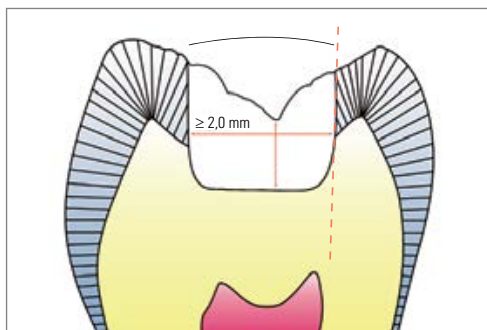
ANTERIOR CROWNS

Incisal: **at least 1.5 mm**
Circumferential: **at least 1.0 mm**



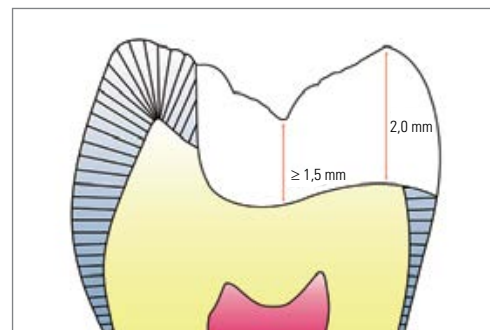
POSTERIOR CROWNS

At the bottom of the fissure: **at least 1.5 mm**
In the area of the cusps: **at least 1.5-2.0 mm**
Circumferential: **at least 1.0 mm**



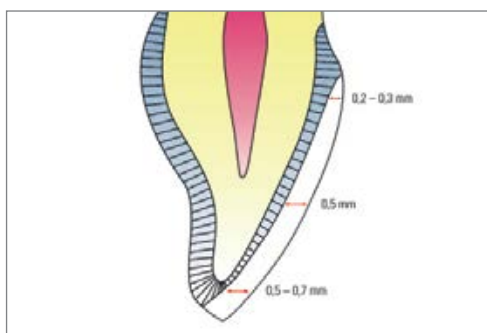
INLAYS

At the bottom of the fissure: **at least 1.5 mm**
In the area of the isthmus: **at least 1.5 mm**
Opening angle: **$>10^\circ$**



ONLAYS

At the bottom of the fissure: **at least 1.5 mm**
In the area of the cusps: **at least 2.0 mm**



VENEERS

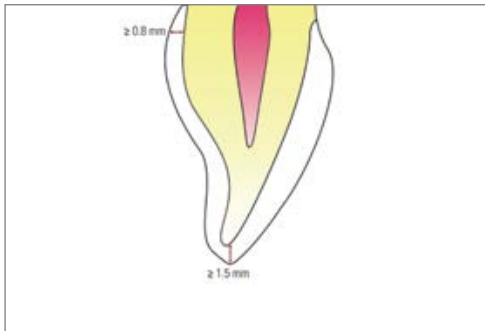
Cervical third: **at least 0.2-0.3 mm**
Central third: **at least 0.5 mm**
Incisal third: **at least 0.5-0.7 mm**

Note: Etching with VITA Ceramics Etch 5% HF acid for 60 seconds, rinsing, drying and silanizing is required on VITABLOCS restorations.

VITA ENAMIC® and VITA ENAMIC® IS Preparation Design

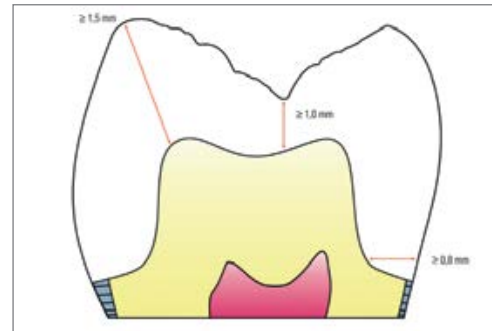


To ensure success of restorations made from VITA ENAMIC, adhere to the following **minimum layer thickness** guidelines. Acceptable margins: chamfer, accentuated chamfer, shoulder prep or step with rounded inner edge.



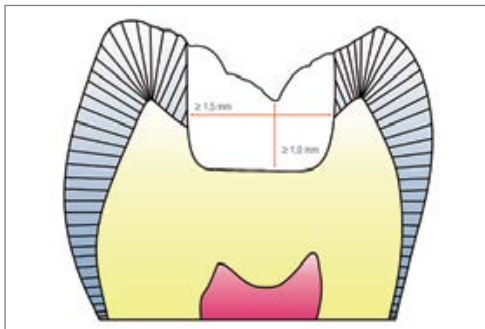
ANTERIOR CROWNS

Incisal: **at least 1.5 mm**
Circumferential: **at least 0.8 mm**



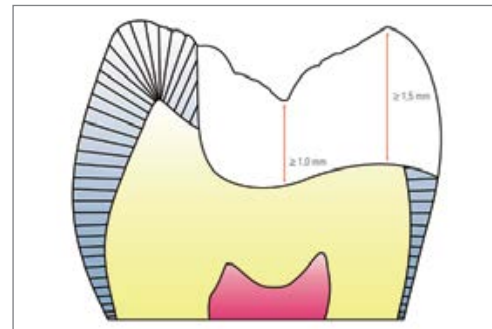
POSTERIOR CROWNS

At the bottom of the fissure: **at least 1.0 mm**
In the area of the cusps: **at least 1.5 mm**
Circumferential: **0.8–1.5 mm**



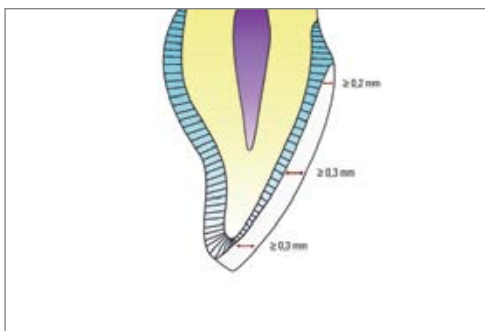
INLAYS

At the bottom of the fissure: **at least 1.0 mm**
In the area of the isthmus: **at least 1.5 mm**



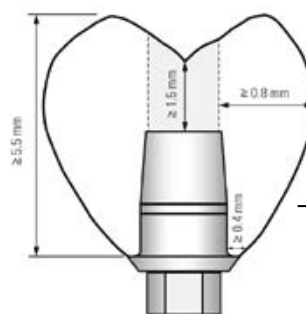
ONLAYS

At the bottom of the fissure: **at least 1.0 mm**
In the area of the cusps: **at least 1.5 mm**



VENEERS

Cervical third: **at least 0.2 mm**
Central third: **at least 0.3 mm**
Incisal third: **at least 0.3 mm**



For posterior screw-retained VITA ENAMIC IS implant restorations

The minimum interarch space required is approximately 5.5 mm.

Note: Etching with VITA Ceramics Etch 5% HF acid for 60 seconds, rinsing, drying and silanizing is required on VITA ENAMIC restorations.

VITA ENAMIC® Bonding to Tooth Structure

Condition the Restoration

Appropriate acid etching (e.g. VITA ADIVA CERA-ETCH 5% hydrofluoric acid / 60 sec) and use of silane (e.g. VITA ADIVA C-PRIME) is required, maximizing the bond to the restoration.

Condition the Tooth

Etch enamel with phosphoric acid gel (e.g. VITA ADIVA TOOTH-ETCH), 35% /30 sec. Spray clean for 30 sec and dry for 20 sec. Control: etched surface must be white opaque. Apply an adequate primer/bonder system (e.g. VITA ADIVA T-BOND) on to the etched tooth substance.

Cement

Use a composite resin cement and either light or dual cure.


- **Light Cure:**
 - Only for thin ceramics like veneers.
- **Dual Cure:**
 - Needed for thick ceramic and opaque restorations.
 - Light cure for a few seconds in order to remove excess.
 - Fully cure using appropriate manufacturer instructions.

Remove Excess Cement

- Clean excess bonding cement.
- Cement removal should be parallel, not perpendicular, to avoid cement pull out.

Common Mistakes to Avoid

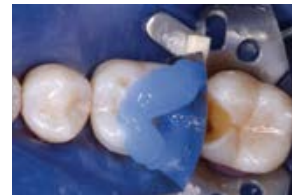- Using expired materials or mixing and matching brands could cause the bond to not cure or set correctly.
- Restoration and/or tooth structure contamination:
 - Clean restoration with alcohol to remove any debris
 - Make sure air lines are free of oil or moisture
 - Contamination from finger oils or saliva will inhibit bond
- Over-etching ceramic creates a layer of precipitated ceramic that may inhibit the bond.
- Under-etching ceramic may cause insufficient bonding.
- If the cement is too thick, it is more likely that de-bonding will occur
- Light curing should not be used for thick or opaque ceramic, as the light is not strong enough to activate the photo-initiators. This will also happen if the curing light is too weak and/or the wrong wavelength.



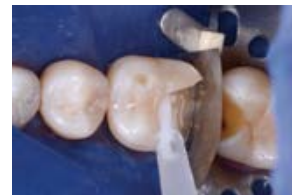Etch the restoration



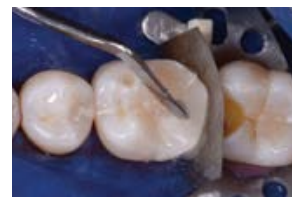Silanizing



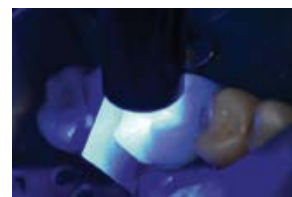Etch the enamel



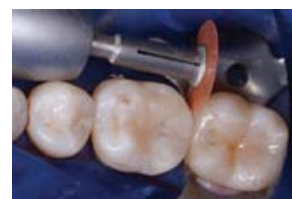Condition the tooth substance



Insertion of the restoration



Light curing



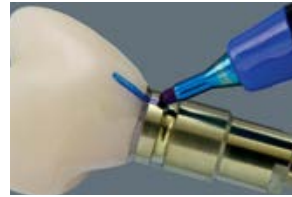
Remove excess cement

VITA ENAMIC® IS Bonding to the Titanium Base

Mark the Crown Position

Place the VITA ENAMIC abutment or crown on the titanium base and mark the positional relation using a waterproof pen. This supports correct subsequent positioning when bonding the crown to the titanium base.

The bonding surfaces of the VITA ENAMIC abutment crown and the titanium base must be free from dust and oil.



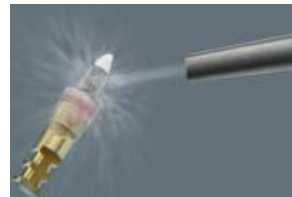Mark position with pen

Condition the titanium base

- Protect the connection surface between the implant and the titanium base with wax or silicone. Seal the screw channel with Teflon tape. Leave some Teflon tape sticking out at the top for easy removal.
- Use high-grade aluminium oxide (Al_2O_3) and carefully sandblast only the bonding surface of the titanium base until a matte surface is obtained.
 - Particle size: 50 μm
 - Pressure: 1.5 bar
- Then remove wax or silicone. Remove the Teflon tape from the screw channel. Clean the titanium base using an ultrasonic bath, with alcohol, or a steam jet and dry using oil-free air.
- The surface to be bonded must not be touched after cleaning, as this can result in contamination and have a negative impact on the adhesive bond.



Seal the screw channel



Sandblast the bonding surface

Note:

The diameter of the titanium base may not be reduced, e.g. by grinding.

To protect the connection surface between the implant and the titanium base, fixation of the titanium base inside a laboratory analog should be carried out.

The contact surfaces of the titanium base may not be sandblasted or processed in any other way!

Shortening the titanium base is not recommended!

VITA ENAMIC® IS Bonding to the Titanium Base

- Apply Monobond Plus using a disposable brush or microbrush.
- Allow Monobond Plus to act for 60 seconds and dry with oil-free air.

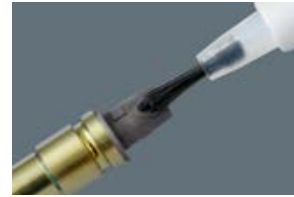Note:

Always observe the instructions for use provided by the manufacturers of the respective products!

- Then seal the screw channel again using a wadding pellet or Teflon tape prior to bonding with the VITA ENAMIC abutment crown.

Condition VITA ENAMIC IS interface

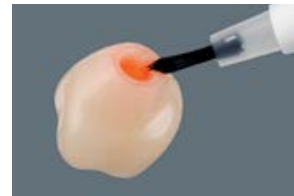
- Cover any polished outer surface to avoid accidental etching.
- Apply VITA ADIVA CERA-ETCH (hydrofluoric acid gel, 5%) to the surfaces to be bonded for 60 seconds.
- Completely remove acid by using water spray or clean in the ultrasonic bath.
- Dry with oil-free air. After drying, the etched surfaces have a whitish opaque appearance.
- Apply silane bonding agent to the etched surface and let dry completely.
- After this preliminary treatment, it is essential that all contamination of the bonding surface is avoided in order to prevent any negative impact on adhesive bonding.
- Mix the Multilink Hybrid Abutment composite in accordance with the specifications provided by the manufacturer and apply to the titanium base and to the interface of the VITA ENAMIC abutment crown.
- Align the VITA ENAMIC abutment crown on the titanium base so that the positional markings are matched.



Apply bonding agent



Seal channel again



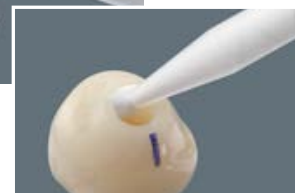Apply ceramics etch



Apply silane



Use a suitable adhesive composite

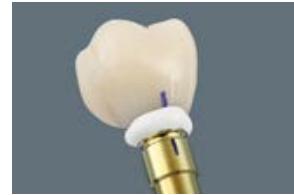

Apply to abutment and crown

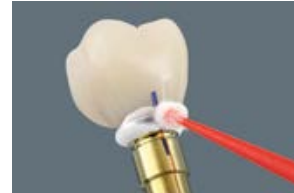- Push the VITA ENAMIC abutment crown onto the abutment until it comes to a stop.
- Make sure it latches into the rotation and position stops!
- While applying even contact pressure, verify both components as well as the correct positional relation in the final position:
- In doing so, do not damage the titanium base.
- Ensure a smooth transition with no gaps between the crown and titanium base.
- Remove the foam pellet from the screw channel.
- Remove any excess material in the screw channel using a microbrush.
- Fix the crown and abutment under contact pressure, do not rotate.
- Depending on the adhesive composite used, carry out polymerization under contact pressure in accordance with the specifications provided by the manufacturer.
- After curing, remove excess bonding agent in the cervical area.
- For final curing of the adhesive composite, apply glycerin gel in the joint gap between VITA ENAMIC and the titanium, as well as in the screw channel, in order to prevent an oxygen inhibited layer.
- If bonding material residue is present in the screw channel, remove it using suitable rotary instruments being careful to not damage the TiBase.
- Polish the adhesive joint using the instruments provided with the VITA ENAMIC Polishing Set and at a low speed (< 5,000 rpm), carefully prepolish the adhesive joint and polish to a high-gloss finish.

Important Note:

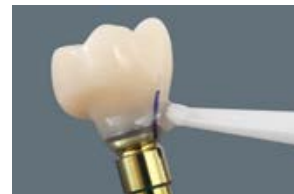Please observe the instructions for use provided by the manufacturers of the respective products!
For a complete set of instructions, refer to VITA literature VITA Implant Solutions Working Instructions (#10150E)



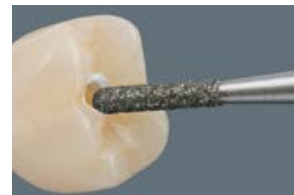Push crown onto abutment



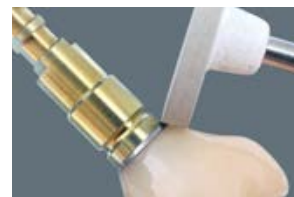
Remove excess material



Apply glycerin gel



Remove bonding material residue




Polish the adhesive joint

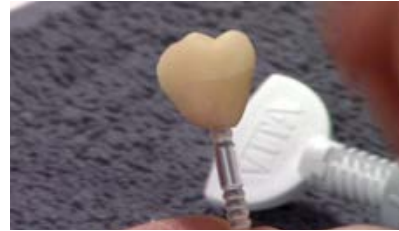VITA ENAMIC® Polishing

Remove the sprue and shape the restoration

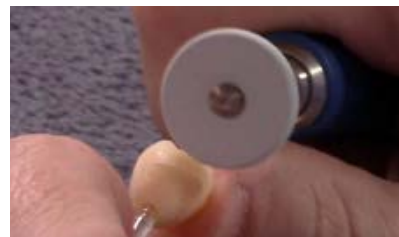- Use a ceramic-friendly rotary instrument to remove the sprue.
- You may also wish to create a pseudo-die with composite to hold the restoration and allow better control over margin polishing.
- Use a VITA grey diamond smoothing wheel to shape and contour the restoration.



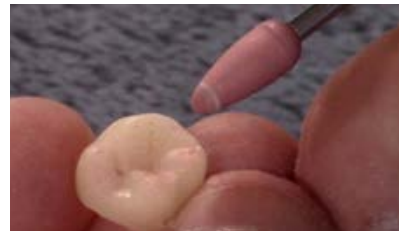1. Remove the sprue.



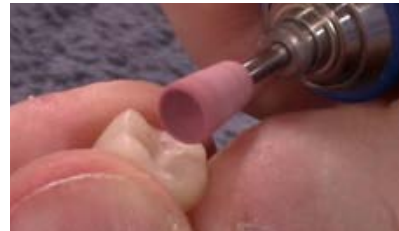2. Create a die to hold the restoration.



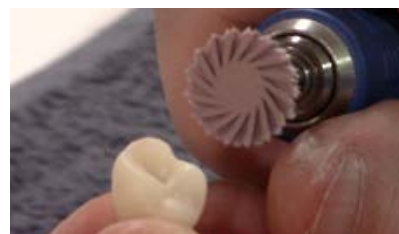3. Shape with diamond wheel.



4. Use the point for grooves.




5. Use the cup on occlusal anatomy.



6. The brush helps with occlusal surfaces.

Pre-polish with the pink polishers

- Use 7,000–10,000 RPM and light pressure.
- Keep moving the polishers around on the surfaces and do not stay in one place too long in order to avoid creating grooves or pits.



VITA ENAMIC Polishing Set clinical - EENPSETCV1



VITA ENAMIC Polishing Set technical- EENPSETT

High-gloss polish with the grey polishers

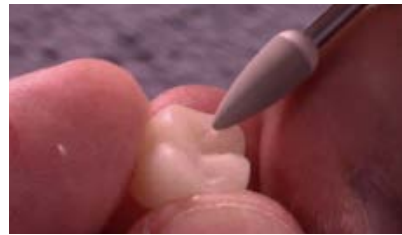- Use 5,000–8,000 RPM and light pressure.
- Keep moving the polishers around on the surfaces and do not stay in one place too long in order to avoid creating grooves or pits.

Important:

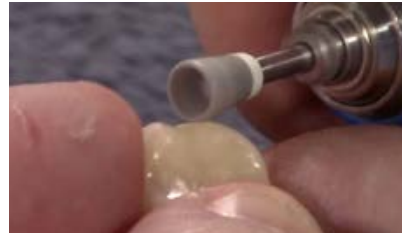- Since dust is formed when grinding, always wear a face mask or grind when wet. Use an extraction unit in the laboratory.
- Do not rework VITA ENAMIC restorations using carbide instruments since these instruments may damage the material. Use only diamond-coated milling tools or special polishers.

For a complete set of VITA ENAMIC processing instructions, refer to the VITA ENAMIC Working Instructions (#1982E)

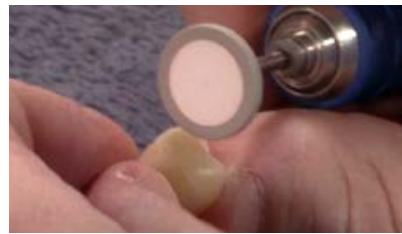Watch the instructional video at
vitanorthamerica.com/ENAMIC



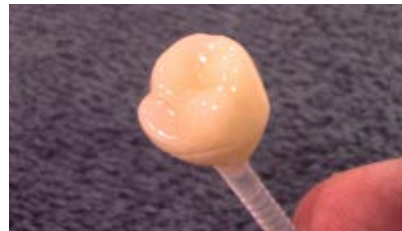
7. High-gloss polish with grey polishers.



8. A nice lustre will form.



9. Finish with the round grey wheel.



10. The final esthetic result.

www.vitanorthamerica.com

800-828-3839 USA
800-263-4778 Canada

VITA